

UDC 616.65-006.6-089.878

Y.A. Nakonechnyi, Yu.O. Mytsyk, A.Y. Nakonechnyi, A.Ts. Borzhievskiy

Personalized preservation extraperitoneoscopic radical prostatectomy in high-risk prostate cancer patients

SNPE «Danylo Halytskyi Lviv National Medical University», Ukraine

Paediatric Surgery (Ukraine). 2025. 3(88): 87-94. doi: 10.15574/PS.2025.3(88).8794

For citation: Nakonechnyi YA, Mytsyk YuO, Nakonechnyi AY, Borzhievskiy ATs. (2025). Personalized preservation extraperitoneoscopic radical prostatectomy in high-risk prostate cancer patients. Paediatric Surgery (Ukraine). 3(88): 87-94. doi: 10.15574/PS.2025.3(88).8794.

Radical prostatectomy (RP) remains one of the most common treatment approaches for localized prostate cancer (PCa). In recent years, it has been increasingly utilized in cases of high-risk prostate cancer (HR-PCa), where achieving an optimal balance between oncological control and functional outcomes is essential.

Aim – to describe and assess the safety and feasibility of personalized preservation extraperitoneoscopic radical prostatectomy (PP-ERP) in patients with HR-PCa.

Materials and methods. PP-ERP was performed in 21 well-informed HR-PCa patients. All patients underwent meticulous preoperative planning based on multiparametric magnetic resonance imaging with a picture quality score ≥ 4 , utilizing 3D modeling. Imaging was interpreted by an experienced, sub-specialized radiologist. The PRECE nomogram was also utilized for surgical planning and for shared decision-making with the patient regarding the extent of tissue preservation. Urinary continence (UC), erectile function (EF), and biochemical recurrence (BCR) were assessed during the follow-up period.

Results. Using the described approach, extraprostatic extension (EPE) was accurately identified preoperatively in 95.2% of cases. At 12 months postoperatively, UC and EF were preserved in 95.2% and 61.9% of patients, respectively, according to the established criteria. Positive surgical margins were observed in 23.8% of cases, and BCR occurred in 19% at 24 months.

Conclusions. PP-ERP with precise surgical planning appears to be a safe and feasible approach for selected HR-PCa patients, offering encouraging functional and oncological outcomes.

This study was conducted in accordance with the principles of the Declaration of Helsinki. The study protocol was approved by the Local Ethics Committee of the institution. The informed consent was obtained from all patients.

The author declares no conflict of interest.

Keywords: radical prostatectomy, personalized preservation, prostate cancer.

Персоналізована презервація при екстраперитонеоскопічній радикальній простатектомії у пацієнтів з раком простати групи високого ризику

Й.А. Наконечний, Ю.О. Мицик, А.Й. Наконечний, А.Ц. Боржієвський

ДНП «Львівський національний медичний університет імені Данила Галицького», Україна

Радикальна простатектомія (RP) залишається одним із найпоширеніших методів лікування локалізованого раку передміхурової залози (РСа). Протягом останніх років її дедалі частіше виконують у випадках РСа групи високого ризику (HR-РСа), де баланс між функціональними та онкологічними результатами є критично важливим.

Мета – описати та оцінити безпеку та доцільність персоналізованої презервації (PP) при екстраперитонеоскопічній радикальній простатектомії (ERP) у пацієнтів із HR-РСа.

Матеріали та методи. PP-ERP виконано у 21 пацієнта з HR-РСа, які були детально проінформовані про ризики та переваги запропонованого підходу. У всіх випадках застосовано ретельне передопераційне планування на основі результатів мультипараметричного магнітно-резонансної томографії, з використанням 3D-моделювання та аналізу якості зображень ≥ 4 , яке проводив досвідчений, вузькоспеціалізований радіолог. Номограму PRECE додатково використано для хірургічного планування та спільного узгодження об'єму презервації з пацієнтом. Протягом періоду спостереження оцінено показники утримання сечі (UC), еректильна функція (EF) та біохімічний рецидив (BCR).

Original articles. Urology and gynecology

Результати. Завдяки описаному підходу екстрапростатичне поширення (EPE) було правильно ідентифіковано у 95.2% випадків. Через 12 місяців після операції УС та ЕФ згідно з установленими критеріями було збережено у 95,2% та 61,9% пацієнтів відповідно. Позитивні хірургічні краї присутні у 23,8% випадків, а біохімічний рецидив виник у 19% пацієнтів протягом 24 місяців.

Висновки. РР-ЕРП із ретельним хірургічним плануванням є безпечним та доцільним підходом для добре відібраних пацієнтів із HR-PCa, демонструючи функціональні та онкологічні результати, що вселяють надію.

Дослідження виконано відповідно до принципів Гельсінської декларації. Протокол дослідження погоджено локальним етичним комітетом установи. На проведення досліджень отримано інформовану згоду пацієнтів.

Конфлікт інтересів відсутній.

Ключові слова: радикальна простатектомія, персоналізована презервація, рак простати.

Radical prostatectomy (RP) remains the gold standard and one of the most frequent approaches for treating localized prostate cancer (PCa) [19,37]. Recent data demonstrate an increasing number of high-risk PCa (HR-PCa) patients opting for this treatment [24]. According to a 2024 meta-analysis by U.G. Falagario, HR-PCa patients face a significantly higher risk of death from the disease, yet they are the group that stands to benefit the most from RP [6]. Given the rising number of younger patients with HR-PCa, achieving optimal functional outcomes is in high demand [16,24], underscoring the critical need for individualized preservation approaches during RP in this patient group [17]. This study introduces adapted surgical techniques for personalized preservation during extraperitoneoscopic radical prostatectomy (PP-ERP) in patients with HR-PCa.

Aim – to describe and evaluate the safety and feasibility of PP-ERP in patients with HR-PCa.

Material and methods of the study

This prospective study includes 21 patients with HR-PCa (according to the EAU risk group stratification) who underwent a PP-ERP between 2020 and 2022, with a 24-month follow-up period. Inclusion criteria were: HR-PCa diagnosed verified by the combined 12-core systemic and target biopsy, MRI prostate imaging quality (PI-QUAL) score of ≥ 4 , examined by a sub-specialized radiologist with 3D-modeling and PRECE nomograms for personalized preservation surgical planning, as well as profound counseling about the oncological and functional risks of this approach [30]. The exclusion criteria were metastatic PCa, finasteride use, and neoadjuvant or adjuvant androgen deprivation therapy. We estimated prostate-specific antigen (PSA), urinary continence (UC), and erectile function (EF) in all cases before and after surgery, as well as throughout the follow-up period. For objective UC estimation, we used ultrasound and uroflowmetry. We defined UC in a dichotomized fashion: continence was considered present if the patient had a voided volume ≥ 200 ml and no leakage during a cough stress test, which was confirmed by objective examination results. EF was defined as an erection sufficient for

penetration and sexual intercourse, with or without the use of a 5-phosphodiesterase inhibitor. All participants had both functions preserved before surgery according to our criteria. Biochemical recurrence (BCR) was defined as two consecutive serum PSA values ≥ 0.2 ng/ml.

Statistical analysis was performed using MedCalc's free statistical calculators and STATISTICA version 10 (64-bit).

The study was performed in accordance with the principles of the Declaration of Helsinki. The study protocol was approved by the Local Ethics Committee for all participants. The informed consent of the patient was obtained for conducting the studies.

Surgical technique. A five port ERP with an anterior approach using a 30° laparoscopic lens was applied in all cases. Bladder neck preservation (BNP) was performed with blunt and sharp dissection using cold scissors and the LigaSure 5 mm Laparoscopic Sealer/Divider (Medtronic, Dublin, Ireland). BNP started laterally and continued dorsally toward the posterior wall of the bladder neck outlet (BNO-PW), followed by further dissection of the posterior and anterior detrusor apron (Fig. 1).

BNP was performed whenever possible, while posterior wall bladder neck outlet preservation (BNO-PW) was done in all cases to preserve the trigonal muscle. After dropping the bladder, dissection continued through the sharply opened Denonvilliers' fascia (DF) along the medial sides of the seminal vesicles (SV) following transection of the vas deferens. Vessel control was carefully performed with an emphasis on avoiding thermal and traction-induced injury to the neurovascular tissue. We employed a combination of precise and gentle placement of Hem-o-lok clips M/L (Weck Closure Systems, Teleflex Medical, Morrisville, NC, USA) alongside the LigaSure device for pinpoint, low-energy cauterization – a technique widely recognized as safe [7]. Moreover, only the tips of the LigaSure device were used, applying short, manually controlled, pinpoint bursts (duration ≤ 2.5 seconds) instead of the automatic mode, to minimize thermal tissue damage. This approach has been reported to decrease thermal tissue damage [29]. Tewari's grading system with incremental nerve-sparing

(NS) principles was applied in all cases [18,42]. After releasing the SV with careful dissection around their tips, an avascular posterior plane between the DF and the prostatic fascia (PF) was developed up to the apex. If oncological risks were present, the dissection plane was performed beneath the DF in accordance with personalized surgical planning (Fig. 2).

Often, during the finalization of posterior avascular plane development, a partial retrograde neurovascular release may be performed, during which the posterior prostatic artery (PA) or its branches can also be identified [31] (Fig. 3).

Next, neurovascular release continues anterolaterally to the SV and the prostate base, aiming to identify anterior PA and its branches' architecture, as well as the predominant neurovascular bundle (PNB) and the accessory neural pathways (ANP) approximate trajectory, regarding the tri-zonal concept [42] (Fig. 4).

Anterior PA and or its branches are usually controlled during this maneuver. At this point, the endopelvic fascia (EF) is bluntly split at the prostate mid-base level, over the PNB, aiming to reach the most convex site of the prostate and develop the anterolateral avascular plane (previously described, Fig. 5) extending toward the prostate-urethral junction [1,4,5,9,22,26,43].

Thus, finalizing the PNB combined release with simultaneous preservation of the anterior-lateral paraprostatic anatomy. At this point, the posterior PA and/or its branches may be seen from the antero-lateral view (Fig. 6).

In patients with a history of inflammation, hydrodissection was used to facilitate the development of surgical planes. When there was a risk of extraprostatic extension (EPE) on the anterolateral side, the EF was incised over the suspicious area, beneath the puboprostatic ligaments (PPL), to preserve oncological safety while maintaining the integrity of the PPL and the distal part of the dorsal vascular complex (DP-DVC). The NS was initiated on the contralateral side of the tumor index site, using a gradual combination of antegrade and retrograde approaches, along with lateral, anterior, and posterior neurovascular release, adapting previously described techniques. [3,13,21,39].

This gradual release approach, combined with active camera optic rotation, ensures better visualization. To prevent damage to neurovascular tissue, the aforementioned vessel control and cold dissection were used, avoiding the use of clips in the para-apical regions (Fig. 7). Para-apical bleeding was managed as needed, following complete neurovascular detachment (Fig. 8).

Further dissection went through the anterior fibromuscular stroma (AFMS) edge, dividing the dorsal vas-

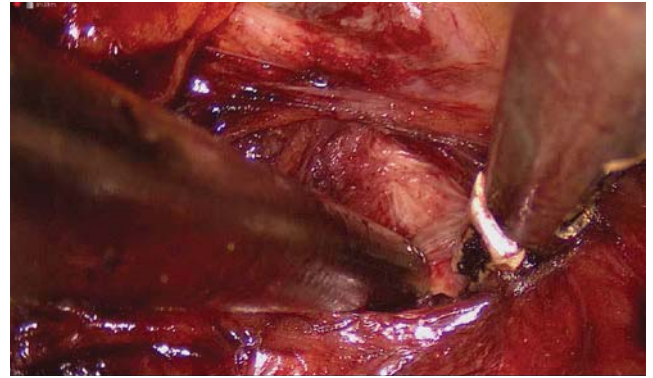


Fig. 1. Blunt dissection between the bladder neck and the prostate base on the right side. Right-side view

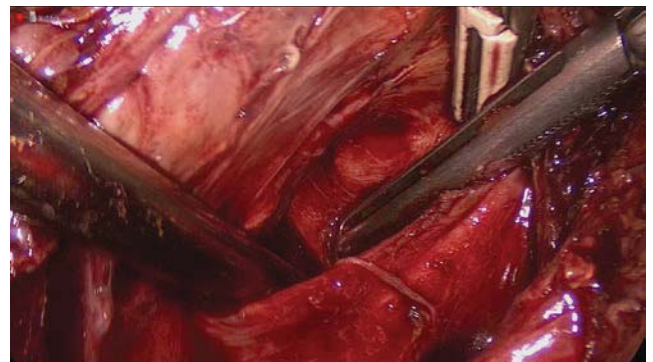

Fig. 2. Different planes developed during blunt posterior dissection

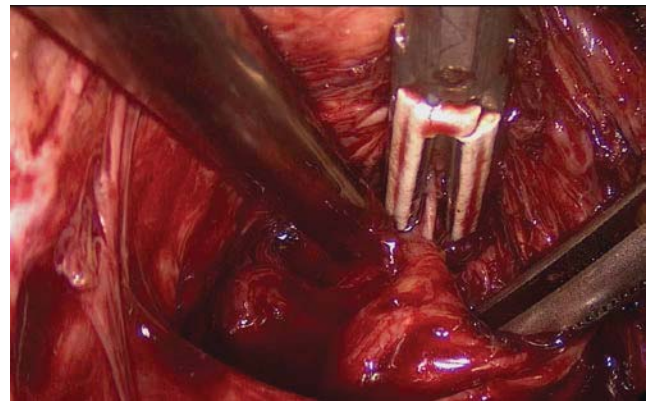


Fig. 3. Identification of the posterior medial prostatic artery on the right side during partial posterior neurovascular release

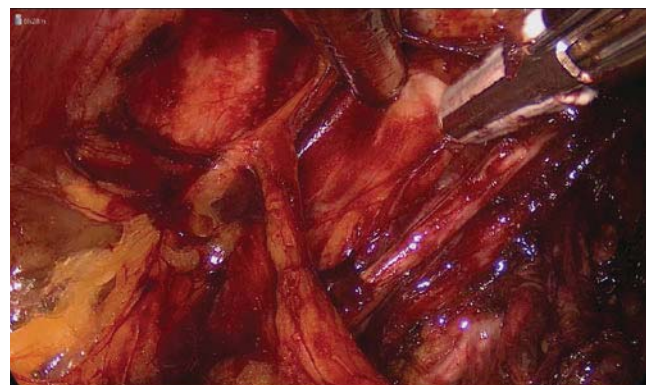

Fig. 4. Blunt dissection of the left anterolateral side

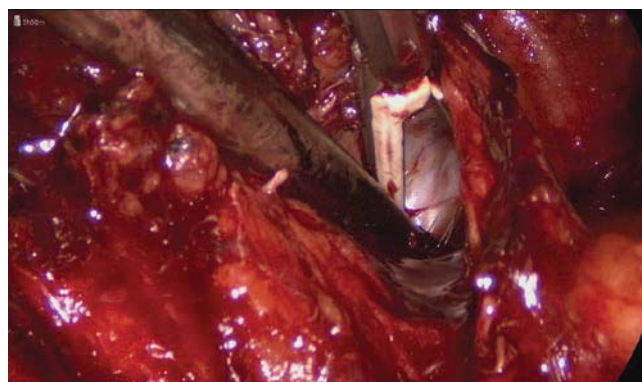


Fig. 5. Anterolateral avascular plane development on the right side. Right-side view

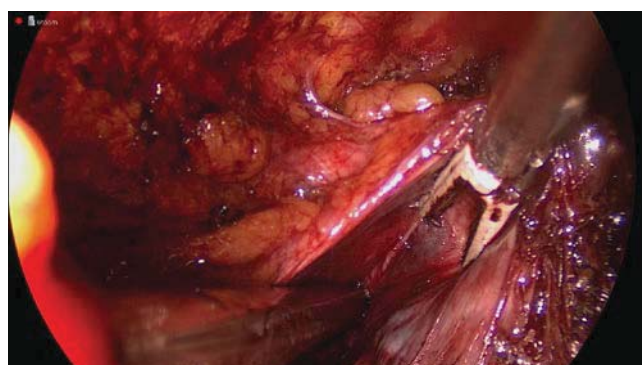


Fig. 6. Anterolateral avascular plane development reaching the prostate-urethral junction on the left side. Left-side view

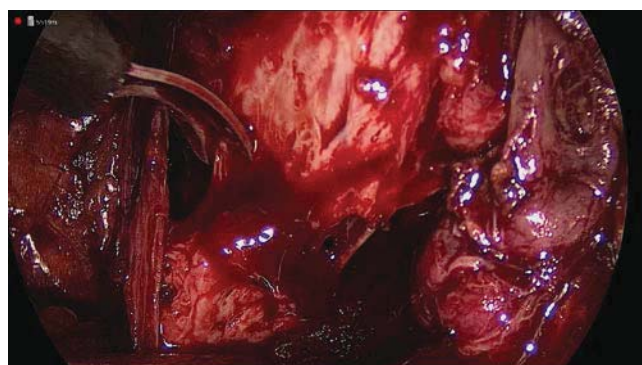


Fig. 7. Antegrade predominant neurovascular bundle (NVB) sparing on the left side. Left-side view

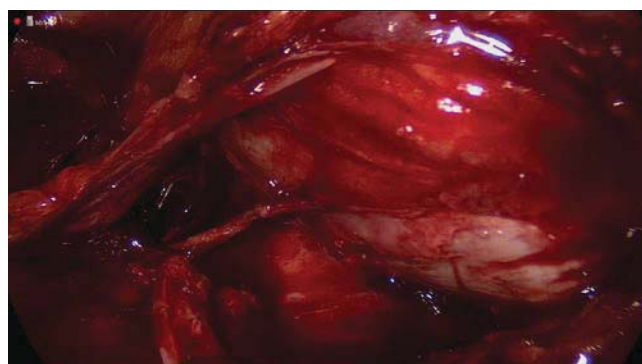


Fig. 8. Neurovascular detachment on the left side, prior to controlling the posterolateral PA branches. Left-side view

cular complex (DVC) with a low-cautery LigaSure use at the prostate mid-base level and with sharp dissection at the prostate apex. Often, blunt dissection may be continued over the urethra before AFMS division (Fig. 9).

After finalized apical dissection, MFUL-P was achieved by the circumflex sharp approach, regarding the apical anatomy [34]. The urethra was divided no more distal than 5 mm from the verumontanum (Fig. 10).

Selective superficial sutures were used for bleeding control on demand to not compromise the neurovascular supply (Fig.11).

Active cold saline irrigation was applied throughout the procedure, which we believe improves tissue recognition and optimizes hemostasis. The extent of lymph node dissection (LND) was determined by individual risk-benefit considerations, following preoperative discussion. Vesicourethral anastomosis (VUA) was performed with SLAR (single-layer anatomical reconstruction) and anterior urethral sphincter preservation (AUS-P), as previously described [27] (Fig. 12).

In cases without oncologic risk according to preoperative parameters, BNP, DVC-P, LPF-P, and posterior DF-P were performed. Conversely, PW-BNO-P, AT with EF-P, PPL-P, DD-DVC-P, and MFUL-P were performed in all cases. This surgical approach was inspired by, based on, and adapted from the previously reported works of leading experts in this field [1,4,5,9,21,22,26,34,40,43].

Results of the study and discussion

The MRI approach using a PI-QUAL score of 4–5, interpreted by subspecialized and experienced radiologists, correctly identified EPE in 90.5% of cases, as confirmed by final pathology.

The study cohort consisted of 21 patients with HR-PCa and a median age of 63 years (Table 1). Patients were generally overweight, with a median body mass index (BMI) of 30.3. The median prostate volume and PSA were 34.6 ml and 11 ng/ml, respectively.

The majority of patients had a preoperative PI-RADS score ≥ 4 . The most common biopsy ISUP grade was 2. However, final pathology showed upgrading in most cases, with a median pathological ISUP grade (pISUP) of 3, underscoring the risk of pathological upgrading.

A significant proportion of the cohort had locally advanced disease, with 52.4% staged as pT3a or pT3b. Specifically, 28.6% were pT3a and 23.8% were pT3b. Lymph node involvement (pN1) was present in 9.5% of patients. The final pathology ISUP distribution showed variability, with ISUP grades 2 and 3 being the most common, together accounting for 57.1% of cases. The positive surgical margin (PSM) rate was 23.8%, and the 24-month BCR rate was 19%. Notably, non-unifocal pathological

Table 1.

Demographic and clinical data of the study group

| Parameter | Study group |
|------------------------------|-------------------|
| Age, years, Me (LQ; UQ) | 63 (61; 68) |
| PSA, ng/ml, Me (LQ; UQ) | 11 (8.91; 22.8) |
| BMI, Me (LQ; UQ) | 30.3 (24.7; 35.8) |
| PV, ml, Me (LQ; UQ) | 34.6 (31.1; 43.6) |
| PIRADS, Me (LQ; UQ) | 4 (4; 5) |
| ISUP, Me (LQ; UQ) | 2 (2; 3) |
| pISUP, Me (LQ; UQ) | 3 (3; 4) |
| OT min, Me (LQ; UQ) | 135 (122; 145) |
| EB, ml, Me (LQ; UQ) | 315 (220; 375) |
| UCR, day, Me (LQ; UQ) | 7 (7; 8) |
| HS, day, Me (LQ; UQ) | 8 (7; 9) |
| T-stage, N (%): | |
| 2c | 10 (47.62) |
| 3a | 6 (28.57) |
| 3b | 5 (23.81) |
| Correctly identified T-stage | 19 (90.5) |
| pT-stage, N (%): | |
| 2c | 10 (47.6) |
| 3a | 6 (28.6) |
| 3b | 5 (23.8) |
| pEPE | 9 (42.9) |
| Unifocal-EPE | 6 (28.6) |
| PSM rate | 5 (23.8) |
| N-stage, N (%): | |
| cN1 | 4 (19) |
| pN1 | 3 (14.3) |
| ISUP grade group, N (%): | |
| 1 | 5 (23.8) |
| 2 | 7 (33.3) |
| 3 | 5 (23.8) |
| 4 | 4 (19) |
| pISUP grade group, N (%): | |
| 2 | 5 (23.8) |
| 3 | 7 (33.3) |
| 4 | 7 (33.3) |
| 5 | 2 (9.5) |
| BCR rate | 4 (19) |
| Side and NS grade, N (%): | |
| Left NS 1 | 2 (9.5) |
| Left NS 2 | 5 (23.8) |
| Left NS 3 | 12 (57.1) |
| Left NS 4 | 2 (9.5) |
| Right NS 1 | 6 (28.6) |
| Right NS 2 | 3 (14.3) |
| Right NS 3 | 8 (38.1) |
| Right NS 4 | 4 (19) |
| NS volume, N (%): | |
| Unilateral full and partial | 8 (38.1) |
| Bilateral partial | 7 (33.3) |
| Unilateral partial and none | 6 (28.6) |

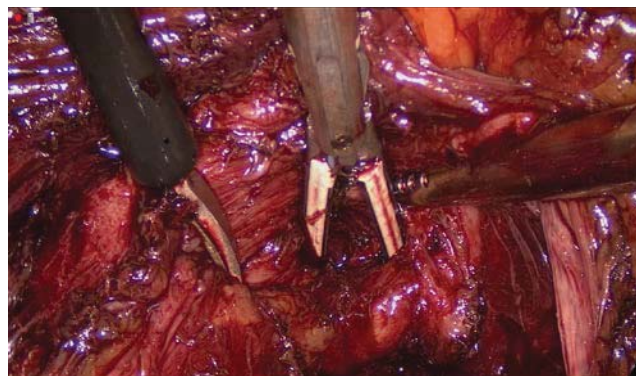


Fig. 9. Blunt dissection over the urethra, beneath the dorsal vascular complex, before division of the anterior fibromuscular stroma. Right-side view

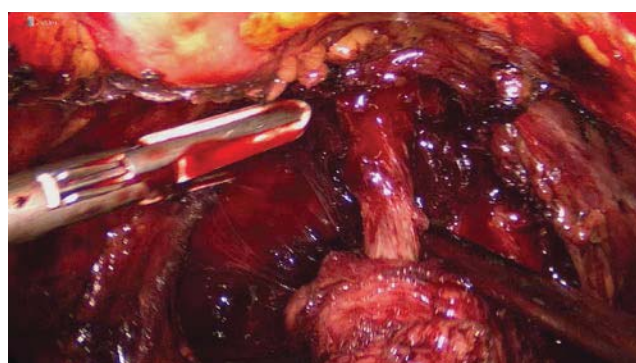


Fig. 10. Maximal preservation of the functional urethral length before lissosphincter dissection

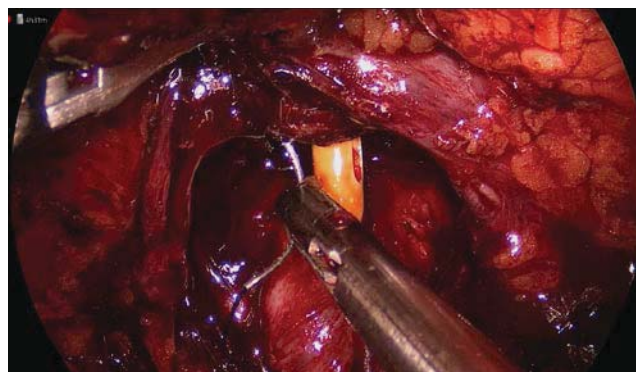


Fig. 11. Control of dorsal vascular complex bleeding using a selective superficial suture

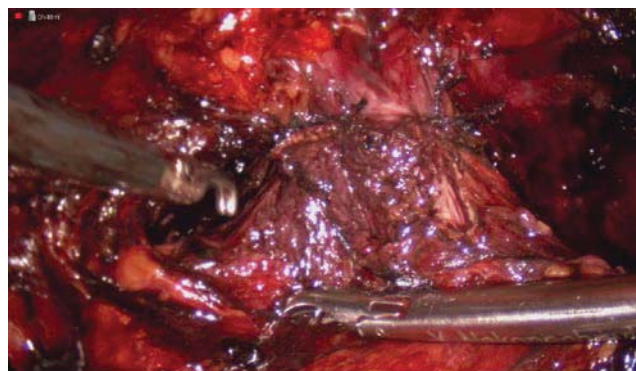


Fig. 12. Final appearance of the vesicourethral anastomosis. Left-side view

Original articles. Urology and gynecology

Table 2

Post-intervention functional outcomes

| Time period after surgery | UC presence, n (%) | EF presence, n (%) |
|---------------------------|--------------------|--------------------|
| 1 month | 66.7 (14) | 33.3 (7) |
| 3 month | 76.2 (16) | 47.6 (10) |
| 6 month | 85.7 (18) | 52.4 (11) |
| 9 month | 90.5 (19) | 57.1 (12) |
| 12 month | 95.2 (20) | 61.9 (13) |

EPE (≥ 3.0 mm) and pN1 status were present in 75% of patients who experienced BCR.

The median operative time (OT) was 135 minutes. The median estimated blood loss (EBL) was 315 ml, reflecting the effectiveness of the hemostatic techniques used. The median urethral catheter removal time (UCR) was 7 days, and the median hospital stay (HS) was 8 days. The postoperative complication rate was 23.8% (5 patients), with all complications classified as grade I according to the Clavien-Dindo classification.

The degree of NS varied between sides. On the left side, most patients (57.1%) received NS grade 3, while on the right side, the distribution was more heterogeneous, with NS grade 3 being the most common (38.1%). In total, 16 NS grade 1–2 procedures were performed across both sides, while NS grade 4 was performed on 6 sides. No bilateral NS grade 1–2 procedures were carried out in this cohort. In 38.1% of cases (8 patients), a unilateral full or partial NS was performed. A bilateral partial NS was performed in 33.3% of cases (7 patients), while 28.6% of cases (6 patients) involved unilateral partial NS combined with no NS on the contralateral side.

At 12 months, 20 (95.2%) patients were continent, and 13 (61.9%) patients had preserved EF, according to established criteria (Table 2).

These results demonstrate the safety and feasibility of this surgical approach in patients with HR-PCa, with oncologic and functional outcomes considered acceptable according to recent reports [8,20,32,36].

Over the last decade, there has been a clear trend toward an increasing number of RPs performed, including in younger patients with HR-PCa [24]. This highlights the growing need to balance quality of life with optimal oncological outcomes, which is particularly crucial for this patient group [13,17].

The evolution of surgical techniques has demonstrated that preservation of periprostatic anatomy can result in superior functional outcomes [12,16]. However, these approaches must be applied cautiously in HR-PCa patients, who face a higher risk of extended or multifocal positive surgical margins (PSMs) [23,32]. Precise pre-

operative estimation of extracapsular extension (EPE) can provide opportunities to adapt surgical techniques for extended preservation without compromising oncological safety or BCR rates. This aligns with recent findings in the literature [8,17,38,45].

Our previous results have already demonstrated the high value of MRI for surgical planning and characterization of prostate cancer [28]. In the present study, EPE was evaluated by an experienced, sub-specialized radiologist, and only cases with a PI-QUAL score ≥ 4 were included, as this is associated with improved diagnostic accuracy [44]. Moreover, recent reports support the reliability of this approach for precise diagnosis and surgical planning [2,15,33]. PRECE nomograms were also used to further estimate EPE risk and facilitate comprehensive presurgical counseling [30].

In our cohort, we applied an incremental NS approach, given its established safety profile [18]. Tumor characteristics and radiologic suspicion of EPE were carefully considered. At sites with suspected EPE, preservation of periprostatic structures was limited, and a higher NS grade (3–4 according to Tewari) was performed to ensure oncological safety. On the contralateral side, NS grade 1–2 was performed, taking into account patient priorities and the inherent risks of HR-PCa.

The combination of gradual posterior, anterior, and lateral PNB release with active camera optic rotation optimized visualization and minimized traction or counter-traction, both of which are associated with neuropraxia [14,21,35,39]. Thermal tissue damage was also considered, and pinpoint, low-energy cauterization was applied as a safe and widely adopted strategy [7,16,25]. Furthermore, recent findings suggest that the use of LigaSure may provide superior oncological outcomes [11]. These considerations are particularly relevant when applying preservation techniques in HR-PCa patients.

We also consider meticulous dissection of the para-apical region to be critical for improved functional outcomes. Our preference is to perform this step using gentle blunt and sharp dissection, with hemostasis achieved after complete NVB detachment. The estimated blood loss EBL in this series reflects the effectiveness of the hemostatic methods applied.

Although the functional and oncological outcomes of this study are promising, further validation in larger cohorts with more robust study designs is required. Nevertheless, our findings are consistent with previously published results [8,20,23].

The main limitations of this study are the small cohort size, its single-surgeon design, and the absence of inter-reader agreement in EPE assessment.

Conclusions

The PP-ERP in patients with HR-PCa appears to be a safe and feasible option, with encouraging functional and oncological outcomes. However, the limited sample size and single-surgeon experience restrict the generalizability of these findings appears to be a safe and feasible option, with promising functional and oncological outcomes.

No conflict of interests was declared by the authors.

References/Література

- Asimakopoulos AD, Corona Montes VE, Gaston R. (2012). Robot-Assisted Laparoscopic Radical Prostatectomy with Intrafascial Dissection of the Neurovascular Bundles and Preservation of the Pubovesical Complex: A Step-By-Step Description of the Technique. *Journal of Endourology*. 26: 1578-1585. <https://doi.org/10.1089/end.2012.0405>.
- Becker AS, Giganti F, Purysko AS, Fainberg J, Vargas HA, Woo S. (2023). Taking PI-QUAL beyond the prostate: Towards a standardized radiological image quality score (RI-QUAL). *European Journal of Radiology*. 165: 110955. <https://doi.org/10.1016/j.ejrad.2023.110955>.
- Bhat KRS, Moschovas MC, Onol FF, Rogers T, Reddy SS, Corder C et al. (2021). Evidence-based evolution of our robot-assisted laparoscopic prostatectomy (RALP) technique through 13,000 cases. *J Robotic Surg*. 15: 651-660. <https://doi.org/10.1007/s11701-020-01157-5>.
- Covas Moschovas M, Bhat S, Onol FF, Rogers T, Roof S, Mazzone E et al. (2020). Modified Apical Dissection and Lateral Prostatic Fascia Preservation Improves Early Postoperative Functional Recovery in Robotic-assisted Laparoscopic Radical Prostatectomy: Results from a Propensity Score-matched Analysis. *European Urology*. 78: 875-884. <https://doi.org/10.1016/j.eururo.2020.05.041>.
- De Carvalho PA, Barbosa JABA, Guglielmetti GB, Cordeiro MD, Rocco B, Nahas WC et al. (2020). Retrograde Release of the Neurovascular Bundle with Preservation of Dorsal Venous Complex During Robot-assisted Radical Prostatectomy: Optimizing Functional Outcomes. *European Urology*. 77: 628-635. <https://doi.org/10.1016/j.eururo.2018.07.003>.
- Falagario UG, Knipper S, Pellegrino F, Martini A, Akre O, Egevad L et al. (2024). Prostate Cancer-specific and All-cause Mortality After Robot-assisted Radical Prostatectomy: 20 Years' Report from the European Association of Urology Robotic Urology Section Scientific Working Group. *European Urology Oncology*. 7: 705-712. <https://doi.org/10.1016/j.euo.2023.08.005>.
- Ficarra V, Novara G, Ahlering TE, Costello A, Eastham JA, Graefen M et al. (2012). Systematic Review and Meta-analysis of Studies Reporting Potency Rates After Robot-assisted Radical Prostatectomy. *European Urology*. 62: 418-430. <https://doi.org/10.1016/j.eururo.2012.05.046>.
- Furrer MA, Sathianathan N, Gahl B, Wuethrich PY, Giannarini G et al. (2023). Functional Impact of Neuro-Vascular Bundle Preservation in High Risk Prostate Cancer without Compromising Oncological Outcomes: A Propensity-Modelled Analysis. *Cancers*. 15: 5839. <https://doi.org/10.3390/cancers15245839>.
- Galfano A, Ascione A, Grimaldi S, Petralia G, Strada E, Boccardi AM. (2010). A New Anatomic Approach for Robot-Assisted Laparoscopic Prostatectomy: A Feasibility Study for Completely Intrafascial Surgery. *European Urology*. 58: 457-461. <https://doi.org/10.1016/j.eururo.2010.06.008>.
- Giganti F, Allen C, Emberton M, Moore CM, Kasivisvanathan V. (2020). Prostate Imaging Quality (PI-QUAL): A New Quality Control Scoring System for Multiparametric Magnetic Resonance Imaging of the Prostate from the PRECISION trial. *European Urology Oncology*. 3: 615-619. <https://doi.org/10.1016/j.euo.2020.06.007>.
- Hamamoto S, AbdelRazek M, Naiki T, Taguchi K, Etani T, Iwatsuki S et al. (2021). LigaSure versus the standard technique (Hem-o-lok clips) for robot-assisted radical prostatectomy: a propensity score-matched study. *J Robotic Surg*. 15: 869-875. <https://doi.org/10.1007/s11701-020-01180-6>.
- Ippoliti S, Colalillo G, Egbury G, Orecchia L, Fletcher P, Piechaud T et al. (2023). Continence-Sparing Techniques in Radical Prostatectomy: A Systematic Review of Randomized Controlled Trials. *Journal of Endourology*. 37: 1088-1104. <https://doi.org/10.1089/end.2023.0188>.
- Kessler TM, Burkhard FC, Studer UE. (2007). Nerve-Sparing Open Radical Retropubic Prostatectomy. *European Urology*. 51: 90-97. <https://doi.org/10.1016/j.eururo.2006.10.013>.
- Kowalczyk KJ, Huang AC, Hevelone ND, Lipsitz SR, Yu H, Ulmer WD et al. (2011). Stepwise Approach for Nerve Sparing Without Countertraction During Robot-Assisted Radical Prostatectomy: Technique and Outcomes. *European Urology*. 60: 536-547. <https://doi.org/10.1016/j.eururo.2011.05.001>.
- Lin Y, Yilmaz EC, Belue MJ, Turkbey B. (2023). Prostate MRI and image Quality: It is time to take stock. *European Journal of Radiology*. 161: 110757. <https://doi.org/10.1016/j.ejrad.2023.110757>.
- Mandel A, Choudhary M, Tillu N, Maheshwari A, Kolanukuduru K et al. (2025). Hood Technique for Radical Prostatectomy. *Journal of Endourology*. 39: S35-S38. <https://doi.org/10.1089/end.2024.0303>.
- Mandel A, Parekh S, Choudhary M, Morizane S, Kacagan C, Tillu N et al. (2025). Analysis of the Current Surgical Anatomical Knowledge of Radical Prostatectomy: An Updated Review. *European Urology*. 20:S0302-2838(25)00344-6. Epub ahead of print. doi: 10.1016/j.eururo.2025.06.002. PMID: 40544124.
- Martini A, Kumarasamy S, Haines KG, Tewari AK. (2019). An updated approach to incremental nerve sparing for robot-assisted radical prostatectomy. *BJU International*. 124: 103-108. <https://doi.org/10.1111/bju.14655>.
- Martini A, Falagario UG, Villers A, Dell'Oglio P, Mazzone E, Autorino R et al. (2020). Contemporary Techniques of Prostate Dissection for Robot-assisted Prostatectomy. *European Urology*. 78: 583-591. <https://doi.org/10.1016/j.eururo.2020.07.017>.
- Martini A, Gandaglia G, Karnes RJ, Zaffuto E, Bianchi M, Gontero P et al. (2019). Defining the Most Informative Intermediate Clinical Endpoints for Predicting Overall Survival in Patients Treated with Radical Prostatectomy for High-risk Prostate Cancer. *European Urology Oncology*. 2: 456-463. <https://doi.org/10.1016/j.euo.2018.12.002>.
- Mattei A, Naspro R, Annino F, Burke D, Guida R, Gaston R. (2007). Tension and Energy-Free Robotic-Assisted Laparoscopic Radical Prostatectomy with Interfascial Dissection of the Neurovascular Bundles. *European Urology*. 52: 687-695. <https://doi.org/10.1016/j.eururo.2007.05.029>.
- Menon M, Shrivastava A, Bhandari M, Satyanarayana R, Siva S, Agarwal PK. (2009). Vattikuti Institute Prostatectomy: Technical Modifications in 2009. *European Urology*. 56: 89-96. <https://doi.org/10.1016/j.eururo.2009.04.032>.
- Moris L, Gandaglia G, Vilaseca A, Van Den Broeck T, Briers E, De Santis M et al. (2022). Evaluation of Oncological Outcomes and Data Quality in Studies Assessing Nerve-sparing Versus Non-Nerve-sparing Radical Prostatectomy in Nonmetastatic Prostate Cancer: A Systematic Review. *European Urology Focus*. 8: 690-700. <https://doi.org/10.1016/j.euf.2021.05.009>.
- Moschovas MC, Jaber A, Saikali S, Sandri M, Bhat S, Rogers T et al. (2024). Impacts on functional and oncological outcomes of Robotic-assisted Radical Prostatectomy 10 years after the US Preventive Service Taskforce recommendations against PSA screening. *Int. braz j urol*. 50: 65-79. <https://doi.org/10.1590/s1677-5538.ibju.2023.0530>.

Original articles. Urology and gynecology

25. Moschovas MC, Patel V. (2022). Neurovascular bundle preservation in robotic-assisted radical prostatectomy: How I do it after 15,000 cases. *Int. braz j urol.* 48: 212-219. <https://doi.org/10.1590/s1677-5538.ibju.2022.99.04>.
26. Myers RP. (2002). Detrusor apron, associated vascular plexus, and avascular plane: relevance to radical retropubic prostatectomy — anatomic and surgical commentary. *Urology.* 59: 472-479. [https://doi.org/10.1016/S0090-4295\(02\)01500-5](https://doi.org/10.1016/S0090-4295(02)01500-5).
27. Nakonechnyi YA. (2025). Intracorporeal square-to-slip knot technique for vesicourethral anastomosis with single-layer anatomical reconstruction and anterior urethral sphincter preservation. *Paediatric Surgery (Ukraine).* 1(86): 73-78. [https://doi.org/10.15574/PS.2025.1\(86\).7378](https://doi.org/10.15574/PS.2025.1(86).7378).
28. Nakonechnyi YA, Mytsyk YuO, Borzhievskiy ATs. (2024). PCA3 score prognostic value for identifying postoperative ISUP grades 4-5 in localized peripheral zone prostate cancer with a posterior tumor growth dominant pattern. *Paediatric Surgery (Ukraine).* 4(85): 65-70. [https://doi.org/10.15574/PS.2024.4\(85\).6570](https://doi.org/10.15574/PS.2024.4(85).6570).
29. Oyama S, Nonaka T, Matsumoto K, Taniguchi D, Hashimoto Y, Obata T et al. (2021). A new method using a vessel-sealing system provides coagulation effects to various types of bleeding with less thermal damage. *Surg Endosc.* 35: 1453-1464. <https://doi.org/10.1007/s00464-020-08043-z>.
30. Patel VR, Sandri M, Grasso AAC, De Lorenzis E, Palmisano F, Albo G et al. (2018). A novel tool for predicting extracapsular extension during graded partial nerve sparing in radical prostatectomy. *BJU International.* 121: 373-382. <https://doi.org/10.1111/bju.14026>.
31. Patel VR, Schatloff O, Chauhan S, Sivaraman A, Valero R, Coelho RF et al. (2012). The Role of the Prostatic Vasculature as a Landmark for Nerve Sparing During Robot-Assisted Radical Prostatectomy. *European Urology.* 61: 571-576. <https://doi.org/10.1016/j.eururo.2011.12.047>.
32. Pellegrino F, Falagario UG, Knipper S, Martini A, Akre O, Egevad L et al. (2024). Assessing the Impact of Positive Surgical Margins on Mortality in Patients Who Underwent Robotic Radical Prostatectomy: 20 Years' Report from the EAU Robotic Urology Section Scientific Working Group. *European Urology Oncology.* 7: 888-896. <https://doi.org/10.1016/j.euo.2023.11.021>.
33. Ponsiglione A, Stanzione A, Califano G, De Giorgi M, Collà Ruvo C, D'Iglio I et al. (2023). MR image quality in local staging of prostate cancer: Role of PI-QUAL in the detection of extraprostatic extension. *European Journal of Radiology.* 166: 110973. <https://doi.org/10.1016/j.ejrad.2023.110973>.
34. Schlomm T, Heinzer H, Steuber T, Salomon G, Engel O, Michl U et al. (2011). Full Functional-Length Urethral Sphincter Preservation During Radical Prostatectomy. *European Urology.* 60: 320-329. <https://doi.org/10.1016/j.eururo.2011.02.040>.
35. Shim JS, Tae JH, Noh TI, Kang SH, Cheon J, Lee JG et al. (2022). Toggling Technique Allows Retrograde Early Release to Facilitate Neurovascular Bundle Sparing During Robot-Assisted Radical Prostatectomy: A Propensity Score-Matching Study. *J Korean Med Sci.* 37: e6. <https://doi.org/10.3346/jkms.2022.37.e6>.
36. Shore N, Hafron J, Saltzstein D, Brown G, Belkoff L, Aggarwal P et al. (2024). Apalutamide for High-Risk Localized Prostate Cancer Following Radical Prostatectomy (Apa-RP). *J Urol.* 212: 682-691. <https://doi.org/10.1097/JU.0000000000004163>.
37. Sood A, Grauer R, Jeong W, Butaney M, Mukkamala A, Borchert A et al. (2022). Evaluating post radical prostatectomy mechanisms of early continence. *The Prostate.* 82: 1186-1195. <https://doi.org/10.1002/pros.24372>.
38. Spirito L, Sciorio C, Romano L, Di Girolamo A, Ruffo A, Romeo G et al. (2025). Impact of Nerve-Sparing Techniques on Prostate-Specific Antigen Persistence Following Robot-Assisted Radical Prostatectomy: A Multivariable Analysis of Clinical and Pathological Predictors. *Diagnostics.* 15: 987. <https://doi.org/10.3390/diagnostics15080987>.
39. Srivastava A, Grover S, Sooriakumaran P, Tan G, Takenaka A, Tewari AK. (2011). Neuroanatomic basis for traction-free preservation of the neural hammock during athermal robotic radical prostatectomy. *Current Opinion in Urology.* 21: 49-59. <https://doi.org/10.1097/MOU.0b013e32834120e9>.
40. Stolzenburg J, McNeill A, Liatsikos EN. (2008). Nerve-sparing endoscopic extraperitoneal radical prostatectomy. *BJU International.* 101: 909-928. <https://doi.org/10.1111/j.1464-410X.2008.07544.x>.
41. Takenaka A, Leung RA, Fujisawa M, Tewari AK. (2006). Anatomy of autonomic nerve component in the male pelvis: the new concept from a perspective for robotic nerve sparing radical prostatectomy. *World J Urol.* 24: 136-143. <https://doi.org/10.1007/s00345-006-0102-2>.
42. Tewari AK, Srivastava A, Huang MW, Robinson BD, Shevchuk MM, Durand M et al. (2011). Anatomical grades of nerve sparing: a risk-stratified approach to neural-hammock sparing during robot-assisted radical prostatectomy (RARP). *BJU International.* 108: 984-992. <https://doi.org/10.1111/j.1464-410X.2011.10565.x>.
43. Wagaskar VG, Mittal A, Sobotka S, Ratnani P, Lantz A, Falagario UG et al. (2021). Hood Technique for Robotic Radical Prostatectomy — Preserving Periurethral Anatomical Structures in the Space of Retzius and Sparing the Pouch of Douglas, Enabling Early Return of Continence Without Compromising Surgical Margin Rates. *European Urology.* 80: 213-221. <https://doi.org/10.1016/j.eururo.2020.09.044>.
44. Wibmer A, Vargas HA, Donahue TF, Zheng J, Moskowicz C, Eastham J et al. (2015). Diagnosis of Extracapsular Extension of Prostate Cancer on Prostate MRI: Impact of Second-Opinion Readings by Subspecialized Genitourinary Oncologic Radiologists. *American Journal of Roentgenology.* 205: W73-W78. <https://doi.org/10.2214/AJR.14.13600>.
45. Yu Y, Reiter RE, Zhang M. (2025). Surgical techniques for enhancing postoperative urinary continence in robot-assisted radical prostatectomy: a comprehensive review. *International Journal of Surgery.* 111: 3931-3941. <https://doi.org/10.1097/JS9.0000000000002414>.

Відомості про авторів:

Наконечний Йосиф Андрійович – PhD, доц. каф. урології ФПДО ДНП «ЛНМУ ім. Д. Галицького». Адреса: м. Львів, вул. Пекарська, 69; тел.: +38 (032) 275-76-32. <https://orcid.org/0000-0002-6872-1889>.

Мицик Юліан Олегович – д.мед.н., проф. каф. урології ФПДО ДНП «ЛНМУ ім. Д. Галицького». Адреса: м. Львів, вул. Пекарська, 69. <https://orcid.org/0000-0002-8513-2349>.

Наконечний Андрій Йосифович – д.мед.н., проф., зав. каф. дитячої хірургії ДНП «ЛНМУ ім. Д. Галицького». Адреса: м. Львів, вул. Пекарська, 69. <https://orcid.org/0000-0003-1402-6642>.

Боржівський Андрій Цезарович – д.мед.н., проф., зав. каф. урології ФПДО ДНП «ЛНМУ ім. Д. Галицького». Адреса: м. Львів, вул. Пекарська, 69. <https://orcid.org/0000-0003-4782-0359>.

Стаття надійшла до редакції 26.04.2025 р., прийнята до друку 16.09.2025 р.