

UDC 616.721.2-002+613.67:617+617.57/.58-001.45-089.81

V.V. Nehoduiko¹, S.V. Tertyshnyi^{2,3}, I.P. Khomenko⁵, A.P. Ryzhenko⁴, S.L. Ocheretnyi⁴,
R.S. Vastyanov³

Peculiarities of liver foreign bodies (metal fragments) removal of gunshot origin depending on their location

¹*Military Medical Clinical Centre of the Northern Region of the Command of Medical Forces,
Armed Forces of Ukraine, Kharkiv, Ukraine*

²*Military Medical Clinical Centre of the Southern Region of the Command of Medical Forces,
Armed Forces of Ukraine, Odesa, Ukraine*

³*Odesa National Medical University, Odesa, Ukraine*

⁴*Military Medical Clinical Centre of the Central Region of the Command of Medical Forces,
Armed Forces of Ukraine, Vinnytsia, Ukraine*

⁵*Shupyk National Healthcare University of Ukraine, Kyiv*

Paediatric Surgery (Ukraine). 2025. 3(88): 63-70. doi: 10.15574/PS.2025.3(88).6370

For citation: Nehoduiko VV, Tertyshnyi SV, Khomenko IP, Ryzhenko AP, Ocheretnyi SL, Vastyanov RS. (2025). Peculiarities of liver foreign bodies (metal fragments) removal of gunshot origin depending on their location. Paediatric Surgery (Ukraine). 3(88): 63-70. doi: 10.15574/PS.2025.3(88).6370.

Aim – to determine the possibility and expediency of removing foreign bodies of the liver (metal fragments) of gunshot origin, located in the VII–VIII segments of the liver, using thoracoscopy and ferromagnetic instruments.

Materials and methods. Wounded patients with gunshot-related foreign bodies (FB) in the liver were randomized into two groups. The main group (82 observations) was formed in the period 2022–2025 and used the proposed methods of FB diagnosis and removal; the comparison group (80 observations) was formed in 2014–2022 and used traditional methods of FB diagnosis and removal. A clinical analysis was conducted using two wounded patients who underwent the removal of foreign bodies (metal fragments) from the liver. To access the VII–VIII segments of the liver, thoracoscopy and diaphragmotomy were used. Identification of fragments was carried out under visual control and intraoperative use of an electron-optical transducer. Removal of metal fragments was carried out with ferromagnetic tools.

Results. Taking into account the peculiarities of the location of metal fragments in the VII–VIII segments of the liver, the absence of bleeding and bilious removal of fragments at the previous stages of medical care, the removal of fragments was not carried out. The use of thoracoscopy, diaphragmotomy, intraoperative visualization, the use of an electron-optical converter, and the removal of fragments with the help of ferromagnetic instruments made it possible to complete the surgical intervention in a minimally invasive way, without complications in the postoperative period.

Conclusion. The use of thoracoscopy with a diaphragmotomy when metal fragments of gunshot origin are located in the VII–VIII segments, with subsequent removal of fragments using magnetic surgical instruments, allows for avoiding laparotomy and completing the surgical intervention in a minimally invasive way.

The study was performed in accordance with the principles of the Declaration of Helsinki. The study protocol was approved by the Local Ethics Committee for all participants.

The informed consent of the patient was obtained for conducting the studies.

No conflict of interests was declared by the authors.

Keywords: gunshot wounds of the liver, magnetic surgical instruments, thoracoscopy.

Original articles. Abdominal surgery

Особливості видалення сторонніх тіл (металеві осколки) печінки вогнепального походження залежно від їх локалізації

В.В. Негодуйко¹, С.В. Тертишний^{2,3}, І.П. Хоменко⁵, А.П. Риженко⁴, С.Л. Очеретний⁴, Р.С. Вастьянов³

¹Військово-медичний клінічний центр Північного регіону Командування медичних сил ЗСУ, м. Харків, Україна

²Військово-медичний клінічний центр Південного регіону Командування медичних сил ЗСУ, м. Одеса, Україна

³Одеський національний медичний університет, Україна

⁴Військово-медичний клінічний центр Центрального регіону Командування медичних сил ЗСУ, м. Вінниця, Україна

⁵Національний університет охорони здоров'я України імені П.Л. Шупика, м. Київ

Мета – визначити можливість та доцільність видалення сторонніх тіл печінки (металеві осколки) вогнепального походження, що розташовані в VII–VIII сегментах печінки з використанням торакоскопії, трансдіафрагмального доступу та використанням феромагнітного інструментарію.

Матеріали та методи. Поранені зі сторонніми тілами (СТ) печінки вогнепального походження були рандомізовані на дві групи: основну (82 спостереження) сформовано в період 2022–2025 рр., в якій використовувалися запропоновані методи діагностики та видалення СТ; порівняння (80 спостережень) – була сформована у 2014–2022 рр., в якій застосовувалися традиційні методи діагностики та видалення ІТ. Проведено клінічний аналіз на прикладі 2-х поранених, яким виконано видалення сторонніх тіл (металевих осколків) із печінки. Для доступу до VII–VIII сегментів печінки застосовано торакоскопію та трансдіафрагмальний доступ видалення сторонніх тіл печінки. Ідентифікацію уламків проведено в передопераційному періоді шляхом проведення КТ органів черевної порожнини та під візуальним інтраопераційним контролем із застосуванням електро-оптичного перетворювача. Видалення металевих уламків здійснено феромагнітним інструментарієм під динамічним спостереженням електро-оптичного перетворювача.

Результати. З огляду на особливості анатомічного розташування металевих осколків у VII–VIII сегментах печінки, відсутність кровотечі та жовчерей, видалення осколків на попередніх етапах медичної допомоги не було проведено. Використання торакоскопії, трансдіафрагмального доступу, динамічної інтраопераційної візуалізації, використання електронно-оптичного перетворювача та видалення осколків за допомогою феромагнітного інструментарію дало змогу виконати операційне втручання малоінвазивним шляхом, без ускладнень протягом операції та в післяопераційному періоді.

Висновок. Застосування торакоскопії у пацієнтів із вогнепальними торакоабдомінальними пораненнями з наявністю осколків вогнепального походження у проекції VII–VIII сегментів із подальшим видаленням осколків за допомогою магнітного хірургічного інструментарію дає змогу уникнути лапаротомії і завершити оперативне втручання малоінвазивним шляхом.

Дослідження було проведено відповідно до принципів Гельсінської декларації. Протокол дослідження було схвалено Локальним етичним комітетом зазначеної в роботі установи.

На проведення досліджень було отримано інформовану згоду пацієнтів.

Автори заявляють про відсутність конфлікту інтересів.

Ключові слова: вогнепальні поранення печінки, магнітний хірургічний інструментарій, торакоскопія.

Introduction

Combat injuries of the abdomen are one of the most complex fields of military surgery. The number of abdominal injuries in the general structure of combat injuries ranges from 1.9 to 9.8% [2]. It was equal to 4–7% (in different military fields and depending on the nature of military operations) according to the first Anti-Terrorist Operation (ATO) years [4]. The frequency of abdominal injuries in Iraq (2003–2011) and Afghanistan (2001–2014), according to the coalition medical service data, varies from 8 to 17% [2,25]. Thus, the average sanitary losses from abdominal injuries are in the range 4.0–8.1% [24,25,30].

Integrated statistics provide surgeons with the following data: about 15% of patients are administered with mild injuries, 10% of them – with moderate injuries, and 75% – with severe injuries, while traumatic shock of different severity is observed in 65% of the wounded and injured, and terminal conditions are observed in 5% of all cases. Additionally, it is worth mentioning that the isolated internal organ injuries are observed only in 14%

of the wounded, multiple injuries are observed in 20% of cases, and combined injuries are observed in 66% [2,25,26]. The most common organs injured are the small bowel (50%), large bowel (40%), liver (30%), and intra-abdominal vessels (25%) [29].

The explosive trauma was the cause of military personnel's death in 70% of cases. Some decrease in the frequency of abdominal wounds to 4% during the wars of the last decade is due to the widespread use of modern means of individual and collective defense [9].

The frequency of liver injuries in these conditions ranges from 8.4% to 29.3%. According to ATO/Joint Forces Operation data, the frequency of liver injuries is equal to 24–35% of all abdominal wounds, while it ranges from 20% to 22%, according to literature data. There are high mortality rates, which ranged from 1.3% to 29.3% during the wars of the last century and averaged to 8.1% [2,3,23].

The liver is second only to the intestine in terms of injury frequency [6]. Meanwhile, the mortality rate for blunt liver trauma reaches 50%, gunshot wounds –

Table 1

Surgical interventions distribution depending on the scope of the surgical intervention, during which FB were removed

Stage of surgical intervention		
On the liver, n=121 (100%)		FB removal, n=56 (100%)
Liver wounds diathermocoagulation	52 (43)	32 (57.1)
Liver tamponade	21 (17.3)	6 (10.7)
Liver wound suturing	30 (24.8)	8 (14.3)
Not performed	18 (14.9)	10 (17.9)

46.1%, stab wounds – 10.5% [20,22]. It should be considered that clinical data concerning liver injury outcomes are underestimated since a large number of wounded die at the place of accident or during transportation [10,16]. The severe intra-abdominal bleeding is the main cause of liver injuries and harsh outcomes; therefore, the surgical intervention timeliness and the choice of an adequate hemostasis method are of particular importance [29]. At the same time, the surgeon is obliged to minimize the risk of developing severe intra-abdominal complications, the incidence of which reaches 17–33% [4,28].

Considering the high frequency of liver injuries equal to 24–35%, the time decrease from the moment of injury till the moment of qualified surgical care provided on the II level of medical support, the use of Damage Control Surgery tactics resulted in an increase in the frequency of seriously injured patients' admission to the next stages of medical evacuation [2,9,14].

Aim: to determine the possibility and reasonability of removing liver foreign bodies (FB) (metal fragments) of gunshot origin located in the VII–VIII liver segments with the help of thoracoscopy and transdiaphragmatic access using ferromagnetic instruments.

Materials and methods of the study

The 162 wounded with liver FB of gunshot origin were randomized into two groups. The main group (82 observations) was formed from February 2022 to February 2025, in which the proposed methods of FB diagnosis and removal were used. The group of comparison (80 observations) was formed from May 2014 to January 2022, in which traditional methods of FB diagnosis and removal were used. All patients were male, and the average age was equal to 43.2 ± 3.6 years.

Clinical research methods included the analysis of complaints, the study of both anamnesis and examination data. Instrumental research methods included fluorography, radiography, computed tomography (CT) and ultrasound investigation.

X-ray studies were performed using a digital mobile diagnostic X-ray system for general purposes «CORSIXDR 2021», and a radiographic and fluorosco-

pic system «OPERAT 30CS 2019». Multispiral CT was performed after radiographic and fluoroscopic examination using a CT scanner of the head, neck, chest, and abdominal cavity «TSX 303 Aquilion Prime 2016».

Ultrasound investigation was performed using «SAMSUNG HM 70 EVO» ultrasound diagnostic scanner with «CA2–8AD» 2–8 MHz, «LA3–16AD» 3–14 Hz (2021) sensor and a «PHILIPS LUMILY» portable ultrasound diagnostic device with contact Intraoperative sensors «C5–2» 2 MHz and «L12–4» 4–12 MHz (2021). This method was used to determine the number, size, density, and depth of FB location, the presence of an acoustic shadow, and attachment to vascular structures. FB metallic density is visualized as a hyperechoic formation with relatively clear contours and a clear acoustic shadow using ultrasound investigation [25,26].

Videothoracoscopy and videolaparoscopy were performed on the videoendoscopic stand using an endoscopic visualization system «RZMedizintechnik GmbH, 2022» and an endoscopic visualization system «Karl Storz, 2021».

Magnetic detection was performed using the following tools: a multifunctional magnetic instrument for metallic ferromagnetic FB diagnosis and removal, an endoscopic magnetic instrument for FB removal from the pleural or abdominal cavity [27].

Examinations were provided during the wounded admission to surgical clinics of Military Medical Clinical Centres (MMCCs) of the Northern, Central and Southern Regions of the Command of Medical Forces (CMF), Armed Forces of Ukraine (AFU) and included general clinical, biochemical, coagulological and immunological studies with blood group and Rh determination, hepatitis B and C, HIV and RMP (with the patient's consent) identification according to generally accepted methods.

Results of the study and discussion

The main factors that determined the indications for liver surgery were the following: the presence of free fluid in the abdominal cavity as a result of liver injury, ongoing bleeding from the liver, and the area of liver damage. Liver FB removal in the majority of cases is a stage

Original articles. Abdominal surgery

Table 2

The wounded distribution with FB's in the liver depending by surgical access

Surgical access	Groups randomized		Totally
	Main group	Comparison group	
Laparotomy	25 (61)	74 (92.6)	99 (81.8)
Thoracotomy	1 (2.4)	3 (3.7)	4 (3.3)
Laparoscopic	9 (21.9)	0	9 (7.4)
Thoracoscopic	2 (5)	0	2 (1.7)
Accesses combination	4 (9.7)	3 (3.7)	7 (5.8)
Totally	41 (33.9)	80 (66.1)	121 (100)

of liver surgery; in rare cases, it is an independent surgical intervention aimed at FB removal.

One could see the distribution of surgical interventions depending on the surgical intervention scope, during which the FB were removed (Table 1).

Therefore, the following results were received according to surgical interventions distribution depending on their size in which FB's were removed: a larger number (32 that equal to 57.1%) of FB's was removed in 52 surgical interventions (43%) with liver wounds diathermo-coagulation, 8 (14.3%) FB's were removed in 30 surgical interventions (24.8%) with liver wounds suturing, 6 (10.7%) FB's were removed in 21 surgical interventions (17.3%) with liver tamponade and 10 (17.9%) FB's were removed in 18 surgical interventions (14.9%) without the liver wounds treatment. This distribution is in favour of the organ-preserving approach to liver tissues.

During the treatment of wounded in the abdomen with liver damage and FB's presence in the liver, the following approaches were used: laparotomic, thoracotomy, laparoscopic, thoracoscopic, and a combination of approaches. One could analyze their distribution in randomized groups of wounded with FB's presence in the liver, depending on surgical access (Table 2).

The most common liver FB's surgical treatment was via laparotomic access – 99 (81.8%) cases, the next in

decreasing frequency of use was laparoscopic access – 9 (7.4%) cases, combination of accesses – 7 (5.8%) cases, followed by thoracotomy – 4 (3.3%) and thoracoscopy – 2 (1.7%) cases < correspondently.

We used thoracoscopic access in 2 patients who received thoracoabdominal wounds during military operations.

Patient X., born in 1993, was delivered through the stages of medical evacuation to MMCC of the Central Region of the CMF AFU on the 4th day after the gunshot wound. Both diagnostic laparoscopy and right pleural cavity drainage by Büllau were performed at the previous stages of medical evacuation the next day after the gunshot wound.

Patient B., born in 1970, was referred by the medical service of the military unit to the MMCC of the Central Region of the CMF AFU two months after the gunshot wound. Diagnostic laparoscopy was performed at the previous stages of medical care on the second day after the gunshot wound.

Patients complained of pain in the right half of the chest and right upper abdomen, which is aggravated by deep inspiration, coughing, and sneezing. Being admitted to MMCC of the Central Region CMF AFU patients underwent general clinical laboratory examinations, abdominal and pleural cavities ultrasound diagnostics,

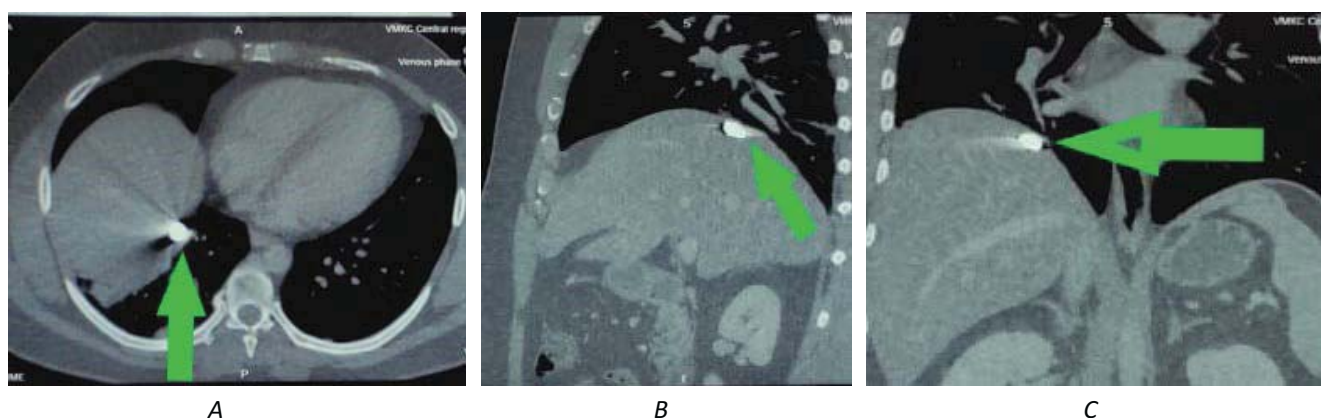


Fig. 1. Results of the chest and abdominal organs multispiral CT: green arrows indicate the metal fragment location along the liver VIII segment diaphragmatic surface: A – axial projection; B – coronal projection; C – sagittal projection

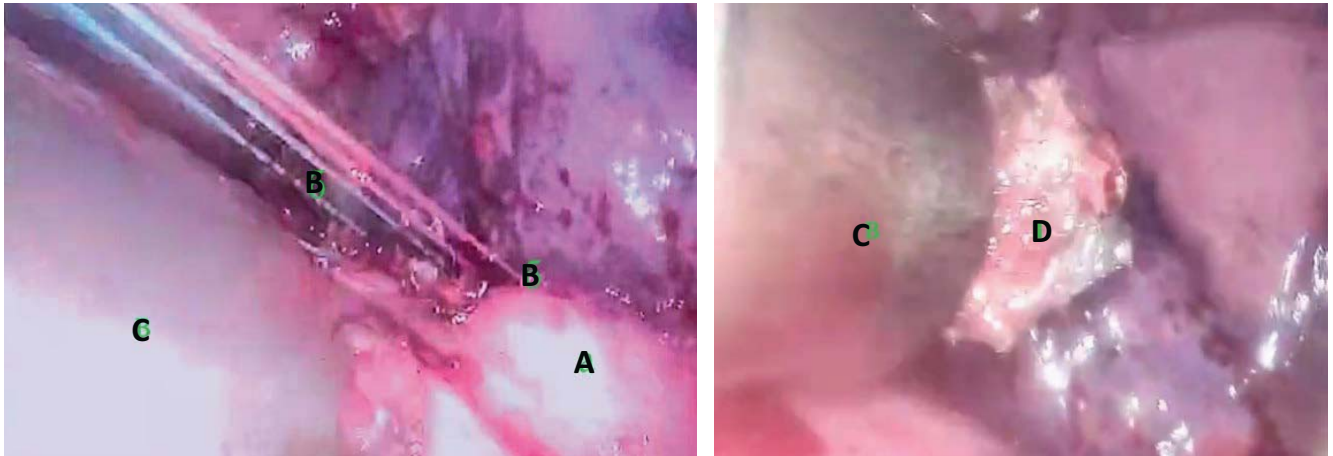


Fig. 2. Videothoracoscopy with metal fragment from the liver removed: fragment A – diaphragm; fragment B – ligatures holding on both edges of the diaphragm injury; fragment C – magnetic tool; fragment D – a metal fragment removed from the liver and fixed on a magnetic tool

and multispiral CT.

Taking into consideration the presence of a thoracoabdominal injury, the multispiral CT obtained results (Fig. 1) and the fragment location peculiarities, a decision was made to perform video-assisted thoracoscopy with subsequent visualization of the diaphragm injury place and the metal fragment removal from the liver.

Taking into account the presence of thoracoabdominal injury, the multispiral CT results, and the fragment location peculiarities, a decision was made to perform video-assisted thoracoscopy with subsequent visualization of the diaphragm injury place and the metal fragment removal from the liver.

The patients underwent surgery after preoperative preparation. Right-sided video-assisted thoracoscopy, metal detection, and liver fragments transdiaphragmatic removal were performed using an endoscopic magnetic tool for FB removal from the pleural or abdominal cavity under the electron-optical converter control.

The following stages of videothoracoscopy were performed, i.e., the diaphragm injury edges fixation, metal detection, and metal fragment fixation using magnetic instruments under the electron-optical converter control and the metal fragment removal (Fig. 2).

Thoracoscopy was completed with right pleural cavity drainage by Büllau.

Diagnostic laparoscopy to monitor bleeding or bile leakage from the liver injury site was the next stage. Laparoscopy ended with the abdominal cavity drainage.

The postoperative period was uneventful. Drains from the abdominal cavity were removed on the 2nd day. Drains from the pleural cavity were removed on the 5th day.

The patients were discharged in satisfactory condition. The bed days were equal to 11 and 8 days, respectively. The patients were referred for rehabilitation.

Thus, our results analysis indicates a significant increase in the specific weight of gunshot liver lesions in abdominal injuries inside the modern combat trauma structure in conditions of military operations throughout the full-scale enemy invasion. It's clear that such intra-abdominal lesions are complex from a medical point of view, taking into account significant intracellular and intraparenchymal destruction, both contusion and ischemia development of the organ or number of organs located in an anatomically dense gastrohepatoduodenobiliary area, which, according to pathophysiological mechanisms, causes an expressed polyfunctional insufficiency formation [15].

Our data demonstrate the efficacy of videothoracoscopic examination of wounded with thoracoabdominal injuries, including liver lesions with gunshot FB presence in its VII–VIII segments located superficially over the liver diaphragmatic surface. The original surgical technique allows for prompt and effective, without complications, surgical intervention in such a contingent of patients.

An additional advantage of the developed and applied method of wounded with liver gunshot wounds is that, due to abdominal injuries, surgical treatment is the possibility of FB intraoperative magnetic detection and removal, which allows for providing minimally invasive surgical intervention and avoiding traumatic laparotomic access.

The efficacy of the original method of wound management and, accordingly, qualified surgical care providing at the II level of medical support is confirmed by the patients' stay in the hospital time reduction – up to 8 days, which corresponds to «Damage Control Surgery» doctrine.

To discuss the data obtained, we consider it reasonable to attract attention to the following four aspects. Firstly,

Original articles. Abdominal surgery

our data do not differ from the existing ones regarding the frequency of minimally invasive treatment of gunshot liver wounds [2,8,24,25,30]. An important aspect of the results obtained, unfortunately, is that we are the only medical specialists who massively treat the wounded with liver gunshot injuries in the event of an ongoing full-scale military aggression against our country [2,13,24]. The remaining similar reports are most often of a household or social nature [1]. Nevertheless, civilization is constantly improving the means and methods of firearms and wounding shells delivery, which, given the ongoing military aggression, only increases the relevance of our clinical observations and treatment of wounded with gunshot intra-abdominal lesions.

Consequently, secondly, the leading task of military doctors is to restore the health of wounded as quickly and efficiently as possible with the least involvement of relevant medical workers' forces and capabilities, which is why there is a constant search for fundamentally new methods of treating wounded people and military personnel. It's a new direction in the soft tissues gunshot wounds non-operative treatment with a modern magnetic instrument used for metal FB's located superficially search and remove [5,7,17,27]. The advantages of using soft tissues FB's magnetic extraction include the following: lower risk of infectious complications, lower risks of both local bloodflow disruption and soft tissues further damage, speed, and efficacy.

Thirdly, we attract attention to gunshot metal FB intra-hepatic localization – in liver VII–VIII segments. It's not always possible to stop bleeding from a crushed liver wound by vessels suturing directly inside the wound, especially in cases of liver VII–VIII segments injury, when retrograde bleeding from the lower vena cava is also possible. The hepatoduodenal ligament clamping is ineffective in this case. Liver resection in an exsanguinated victim may be an unbearable intervention for the patient, especially at the level of primary medical care, in non-specialized conditions. We achieved haemostasis by electrocoagulation, after which the abdominal cavity was cleaned and drained. We would like to stress in this regard that we are not supporters of the well-known tactics of hepatic artery ligation in cases of liver gunshot injuries [11,19] due to direct traumatic liver damage by high-energy wounding, the presence of probable hemodynamic intra-hepatic and systemic disorders. The truth is that the well-known and effective tactic of hepatic artery superselective X-ray endovascular embolization [5,18] is impossible to perform at the II level of medical care in wartime.

In case of bile leakage from the liver-damaged area, we usually perform electrocoagulation, liver rupture suturing, and cholecystostomy.

It is extremely important in this case to stabilize haemodynamics as soon as possible, to restore the affected organ (liver) integrity, to prevent bile leakage and other possible complications development – the only way is to perform and complete the surgical intervention. In general, the high professionalism of surgeons, the wide range of surgical skills and competencies presence in their arsenal give them the opportunity to improve the results of such a contingent of patients surgical treatment, to avoid unwarranted laparotomies, to transfer compensated patients to the next levels of medical care with the perspective goal of a quick return to military service which is currently gaining strategic and governmental importance.

Fourthly, our clinical observations from a fundamental point of view, despite their apparent simplicity, are extremely responsible and require a surgeon's highly specialized training. The fact is that parenchymal intra-abdominal organs injuries by modern high-energy weapons can lead to more complex injuries, neurovascular formations damage, and massive blood loss, loss of consciousness, and rapid death of patients due to multi-functional and multi-organ failure [15].

The entire pathophysiological aspect of the work is that the time of military surgeons' operative work, additionally to medical significance, significantly reduces the time interval for the pathogenetic mechanisms «vicious circle» formation in case of liver (as well as all other intra-abdominal parenchymal organs) gunshot injury by high-energy shells. Hepatic parenchyma damage, hepatocytes necrosis, blood interstitial extravasation with the expressed edema development, and additional alternative impact on hepatocytes' cytoplasm together with capillaries and small blood vessels rupture with a high risk of arterial bleeding, pain, shock, the circulating blood volume reduction, hypoxia, and other pathophysiological phenomena significantly reduce the organisms' overall ability to resist [12,15,21]. The fundamental importance of the obtained clinical results becomes clear through an understanding of the essential and rapidly evolving pathophysiological processes in the body of the wounded. It's clear that the faster doctors manage to stop the bleeding, to restore organ function, and to remove metal FB, the lower the risk of localized edema reaction and compartment syndrome development and subsequent damage to neighbouring tissues and organs [7].

Resuming, we note that thoracoscopy use in patients with gunshot thoracoabdominal wounds with the gunshot fragments presence in liver VII–VIII segments projection with magnetic detection apply and their subsequent remove was proved to be highly effective in

modern conditions on a big contingent of patients due to diagnostic, treatment and recovery process acceleration, laparotomy avoidance and other entirely medical advantages such as stay in the surgical hospital shortened, postoperative complications absence, pharmacological load reduction on a certain patient and a faster return of the injured to military service.

Conclusion

1. Videothoracoscopy in patients with thoracoabdominal injuries with gunshot FB presence in the hepatic VII–VIII segments located superficially on the liver's diaphragmatic surface allows solving the following tasks: the pleural cavity revision and haemothorax removal; liver FB removal using magnetic tools under the electron-optical converter control; diaphragmatic damage elimination.

2. The surgical intervention should be completed with diagnostic laparoscopy to check for the absence of bleeding and bile leakage from the liver injury site, followed by the abdominal cavity drainage.

3. Thoracoscopy use in patients with gunshot thoracoabdominal wounds with the presence of gunshot fragments in the projection of liver VII–VIII segments, with subsequent fragments removed using magnetic surgical tools, allows for avoiding laparotomy and completing the surgical intervention in a minimally invasive way that totally corresponds to «Damage Control Surgery» tactics.

No conflict of interests was declared by the authors.

References/Література

- Baum GR, Baum JT, Hayward D, MacKay BJ. (2022). Gunshot Wounds: Ballistics, Pathology, and Treatment Recommendations, with a Focus on Retained Bullets. *Orthopedic Research and Reviews*. 14: 293-317. doi: 10.2147/ORR.S378278.
- Gumenyuk KV, Khomenko IP, Lurin IA. (2022). Treatment of the wounded with combat injuries of the abdomen (experience of Antiterrorist Operation). *Operation of Joint Forces*. Ed. by V.I. Tsymbalyuk. Kherson: Oldi+.
- Gumenyuk KV, Korol SO, Hybalo RV. (2024). Guidelines for military field surgery. Kyiv: Lyudmila Publishing House.
- Khomenko IP, Gerasimenko OS, Yenin RV, Galushka AM, Kazmirchuk AP. (2018). Features of surgical treatment of gunshot wounds of the abdomen. *Clinical Surgery*. 85(9): 71-74. doi: 10.26779/2522-1396.2018.09.71.
- Khomenko IP, Grechanyk OI, Abdullaev RYa. (2018). X-ray diagnosis of combat surgical trauma: guidelines. Kyiv: Lesya.
- Khomenko IP, Kashtalyan MA, Gaida YaI, Gerasimenko OS, Yenin RV, Khoroshun EM et al. (2019). Features of surgical treatment of gunshot wounds of the liver. *Kharkiv Surgical School*. 1(94): 83-86.
- Khoroshun EM, Makarov VV, Nehoduiko VV, Shypilov SA, Tertyshnyi SV, Vervovkin IV et al. (2024). Non-operative treatment of gunshot wounds of soft tissues. *World of Medicine and Biology*. 2(88): 180-184 doi: 10.26724/2079-8334-2024-2-88-180-184.
- Khoroshun EM, Makarov VV, Panasenko SI, Negoduiko VV, Shipilov SA, Bunin YuV et al (2025). Experience in using SNOM tactics in gunshot wounds of the head, chest, abdomen and soft tissues. *Emergency Medicine*. 21(4): 31-37. <https://doi.org/10.22141/2224-0586.21.4.2025.1884>.
- Khvysiuk OM, Marchenko VG, Mykhaylov BV. (2019). Medical assistance to combatants. Kharkiv: DISA Plus.
- Kozar RA, Moore FA, Cothren CC, Moore EE, Sena M, Bulger EM et al. (2006). Risk factors for hepatic morbidity following nonoperative management: multicenter study. *Arch Surg*. 141(5): 451-458. doi: 10.1001/archsurg.141.5.451.
- Laney DF 4th, Medina D, Fairchild AH, Ustunsoz B, Smith A, Ferral H. (2024). A Synergistic Approach To Acute Liver Trauma: Current Guidelines and the Importance of Collaboration Between Interventional Radiology and Trauma Surgery. *Semin Intervent Radiol*. 41(5): 515-526. doi: 10.1055/s-0044-1792089.
- Lurin IA, Khomenko IP, Kashtalyan MA, Nehoduiko VV, Vastyanov RS, Tertyshnyi SV et al. (2024). Objectivization of surgical tactics in case of covering tissue gunshot defects restoration. *Azerbaijan Medical Journal*. 3: 65-70. <https://doi.org/10.34921/amj.2024.3.011>.
- Lurin IA, Khoroshun EM, Gumenyuk KV et al. (2023). Treatment of wounded with combat injuries of the chest. Ed. by V.I. Tsymbalyuk. Ternopil: TNMU.
- Lurin I, Vorovskiy O, Makarov V, Khoroshun E, Nehoduiko V, Ryzhenko A et al. (2024). Management of thoracoabdominal gunshot injuries by using minimally invasive surgery at role 2 deployed field hospitals in Ukraine. *BMC Surgery*. 24: 183. <https://doi.org/10.1186/s12893-024-02475-3>.
- Moroz VM, Shandra OA, Vastyanov RS, Yoltukhivsky MV, Omelchenko OD. (2016). *Physiology*. Vinnytsia: Nova Knyha.
- Morrison JJ, Bramley KE, Rizzo AG. (2011). Liver trauma – operative management. *J R Army Med Corps*. 157(2): 136-144. doi: 10.1136/jramc-157-02-03.
- Negoduyko VV, Mykhailosov RN, Velikodnyi AN, Kovtun KV. (2019). Investigation of foreign bodies of soft tissues of incendiary origin. *Georgian Medical News*. 12(297): 13-17.
- Prichayudh S, Sirinawin C, Sriussadaporn S, Pak-art R, Kritayakirana K, Samorn P et al. (2014). Management of liver injuries: predictors for the need of operation and damage control surgery. *Injury*. 45(9): 1373-1377. doi: 10.1016/j.injury.2014.02.013.
- Richardson JD, Franklin GA, Lukan JK, Carrillo EH, Spain DA, Miller FB et al. (2000). Evolution in the management of hepatic trauma: a 25-year perspective. *Ann Surg*. 232(3): 324-330. doi: 10.1097/0000658-200009000-00004.
- Ryce AL, Somasundaram A, Duszak R Jr, Newsome J, Majdalany BS, Johnson JO et al. (2023). Contemporary Management of Blunt Liver Trauma: An Analysis of the Trauma Quality Improvement Program Registry (2007-2019). *J Vasc Interv Radiol*. 34(8): 1441-1450. doi: 10.1016/j.jvir.2023.04.018.
- Stefanopoulos PK, Pinialidis DE, Hadjigeorgiou GF, Filippakis KN. (2017). Wound ballistics 101: the mechanisms of soft tissue wounding by bullets. *Eur J Trauma Emerg Surg*. 43(5): 579-586. doi: 10.1007/s00068-015-0581-1.
- Thomas MN, Whaba R, Datta RR, Bunck AC, Stippel DL, Bruns CJ. (2023). Management and treatment of liver injuries after blunt abdominal trauma. *Chirurgie (Heidelb)*. 94(8): 669-674. doi: 10.1007/s00104-023-01858-1.
- Tsymbaliuk VI, Abdullaev RYa, Lurin IA, Lazoryshynets VV, Usenko OY, Dykan IM et al. (2024). Imaging of toracoabdominal gunshot wounds. Kharkiv: Fact.
- Tsymbalyuk VI (ed.). (2020). *Soft tissue gunshot wounds (experience of Antiterrorist Operation / Operation of Joint Forces)* Kharkiv: Collegium.
- Tsymbalyuk VI (ed.). (2021). *Atlas of combat surgical trauma (experience of Antiterrorist Operation. Operation of Joint Forces)*. Kharkiv: Collegium.
- Tsymbalyuk VI (ed.). (2024). *Atlas of Radiological Diagnosis of Gunshot Wounds*. Vinnytsia: TVORY.

Original articles. Abdominal surgery

27. Tsybalyuk VI, Lurin IA, Khoroshun EM, Gumenyuk KV. (2022). The use of modern magnetic and non-magnetic instruments for the diagnosis and removal of foreign bodies. Kharkiv: FOP Brovin O.V.
28. Viridis F, Podda M, Di Saverio S, Kumar J, Bini R, Pilasi C et al. (2022). Clinical outcomes of non-operative management and clinical observation in non-angioembolised hepatic trauma: A systematic review of the literature. Chin J Traumatol. 25(5): 257-263. doi: 10.1016/j.cjtee.2022.04.004.
29. Zarama V, Torres N, Duque E, Arango-Ibañez JP, Duran K, Azcárate V et al. (2024). Incidence of intra-abdominal injuries in hemodynamically stable blunt trauma patients with a normal computed tomography scan admitted to the emergency department. BMC Emerg Med. 24(1): 103. doi: 10.1186/s12873-024-01014-w.
30. Zarutsky YaL, Bilyi VYa et al. (2018). Military Field Surgery. Ed. by Ya.L. Zarutsky, V.Ya. Bilyi. Kyiv: FENIX.

Відомості про авторів:

Негодуйко Володимир Володимирович – д.мед.н., проф., полковник мед. служби, начальник клініки невідкладної медичної допомоги (та прийому і евакуації) ВМКЦ Північного регіону Командування мед. сил ЗСУ; проф. каф. хірургії №4 ХНМУ. Адреса: м. Харків, вул. Культури, 5. <https://orcid.org/0000-0003-4540-5207>.

Тертишний Сергій Володимирович – д.мед.н., доц., підполковник мед. служби, начальник відділення реконструктивно-відновлювальної хірургії ВМКЦ Південного регіону Командування мед. сил ЗСУ; проф. каф. медицини катастроф та військової медицини ОНМедУ. Адреса: м. Одеса, вул. Пироговська, 2. <https://orcid.org/0000-0002-4949-5409>.

Хоменко Ігор Петрович – д.мед.н., чл.-кор. НАМН України, проф., гол. лікар МКЛ №8. Адреса: м. Київ, вул. Ю. Кондратюка, 8. <https://orcid.org/0000-0002-8199-5083>.

Риженко Андрій Петрович – підполковник мед. служби, начальник відділення невідкладної хірургії клініки абдомінальної хірургії ВМКЦ Центрального регіону Командування мед. сил ЗСУ. Адреса: м. Вінниця, вул. Князів Коріатовичів, 185. <https://orcid.org/0000-0003-2979-8231>.

Очеретний Сергій Леонідович – підполковник мед. служби, начальник відділення хірургічної інфекції клініки абдомінальної хірургії ВМКЦ Центрального регіону Командування мед. сил ЗСУ. Адреса: м. Вінниця, вул. Князів Коріатовичів, 185. <https://orcid.org/0009-0000-2230-0264>.

Вастьянов Руслан Сергійович – д.мед.н., проф., зав. каф. загальної та клінічної патологічної фізіології ім. В.В. Підвисоцького ОНМедУ. Адреса: м. Одеса, пров. Валіховський, 2. <https://orcid.org/0000-0001-5108-1945>.

Стаття надійшла до редакції 30.06.2025 р., прийнята до друку 16.09.2025 р.