

UDC 617-089.844-611.018.62-612.75

O.A. Danylov, O.V. Shulha

Optimisation of methods of diagnosis and correction of heel foot in children with cerebral palsy

Shupyk National University of Health of Ukraine, Kyiv

Paediatric Surgery(Ukraine).2023.4(81):49-58; doi 10.15574/PS.2023.81.49

For citation: Danylov OA, Shulha OV. (2023). Optimisation of methods of diagnosis and correction of heel foot in children with cerebral palsy. Paediatric Surgery (Ukraine). 4(81): 49-58. doi: 10.15574/PS.2023.81.49.

The main cause of heel foot is muscle imbalance due to dysfunction of the triceps femoris muscle. Literature data indicate the need to study issues related to changes in the anatomy and function of the foot flexor muscles and calcaneus and to determine indications for optimal methods of correction of heel foot.

Purpose – to study the anatomical and functional changes in the calf muscle and bones in children with heel foot to determine the optimal methods of diagnosis and correction of deformity.

Materials and methods. We analysed the results obtained during the treatment of 14 patients (28 cases) aged 11 to 17 years with cerebral palsy complicated by calcaneal foot formation. Two groups were formed: the main group of 6 patients (12 cases), in which posterior calcaneal osteotomy with Achilles tendon plasty and transposition of the tibialis anterior tendon was performed; the comparison group of 8 patients (16 cases), in which only soft tissue surgery was performed. The comparative group was divided into 2 subgroups, which differed in radiological parameters of Bohler and Kite Danilov angles: the subgroup A – 3 patients (6 cases), the subgroup B – 5 patients (10 cases). Clinical and radiological methods were used to examine patients.

Results. The structure and shape of the calcaneus change in the presence of heel foot, which leads to changes in the Danilov angle and the angles between the trabecular lines. Correction of the shape of the calcaneus is a prerequisite for creating optimal biomechanical gait conditions. Transplantation of the tibialis anterior tendon eliminates the pathological effect of its retraction; achilloplasty eliminates the functional deficiency of the triceps tendon.

Conclusions. The results of surgical correction on soft tissues showed effectiveness at Bohler, Kite $<35^\circ$, Danilov $<40^\circ$ angles. At higher values, it is necessary to supplement the intervention with a posterior calcaneal osteotomy.

The study was conducted in accordance with the principles of the Declaration of Helsinki. The study protocol was approved by the local ethics committees of all institutions participating in the study. Informed consent was obtained from the patients.

No conflict of interests was declared by the authors.

Keywords: heel foot, children, surgical treatment, kinematic muscle chain, bone deformity, muscle anatomy, osteotomy, tendon plastics, bone power lines.

Оптимізація методів діагностики та корекції п'яткової стопи в дітей, хворих на дитячий церебральний параліч

О.А. Данилов, О.В. Шульга

Національний університет охорони здоров'я України імені П.Л. Шупика, м. Київ

Основною причиною виникнення п'яткової стопи є м'язовий дисбаланс унаслідок порушення функції триголового м'яза гомілки. Дані літератури свідчать про необхідність вивчення питань, які стосуються змін в анатомії і функції м'язів-згиначів стопи, п'яткової кістки, а також визначення показань для оптимальних методів корекції п'яткової стопи.

Мета – вивчити анатомічні й функціональні зміни в литковому м'язі та кістках дітей з п'ятковою стопою; розробити оптимальні методи діагностики та корекції деформації.

Матеріали та методи. Проаналізовано показники, отримані на тлі лікування 14 пацієнтів віком від 11 до 17 років із церебральним паралічем, ускладненим формуванням п'яткової стопи. Сформовано дві групи: основна – 6 пацієнтів (12 випадків), у якій проводили

Оригінальні дослідження. Ортопедія

задню остеотомію п'яtkової кістки з пластикою ахіллового сухожилка і транспозицією сухожилка переднього великогомілкового м'яза; порівняльна група – 8 пацієнтів (16 випадків), яку поділено на дві підгрупи відповідно до рентгенологічних показників: підгрупа А – 6 випадків, підгрупа В – 10 випадків, у яких проводили оперативне втручання на м'яких тканинах. Для обстеження пацієнтів використано клінічні та рентгенологічні методи. Отримані дані оброблено статистично з визначенням $M \pm m$, коефіцієнта достовірності за критеріями Стюдента. Значущість встановлено на рівні $p < 0,05 - 0,005$.

Результати. За наявності п'яtkової стопи змінюються структура і форма п'яtkової кістки, що призводить до зміни кута Danilov та кутів між трабекулярними лініями. Необхідною умовою створення оптимальних біомеханічних умов ходи є корекція форми п'яtkової кістки. Пересадка сухожилка переднього великогомілкового м'яза обумовлює усунення патологічного впливу в результаті його ре-тракції; ахіллопластика усуває функціональну недостатність триголового м'яза.

Висновки. Результати хірургічної корекції на м'яких тканинах показують ефективність при кутах Bohler, Kite $< 35^\circ$, Danilov $< 40^\circ$. За більших значень слід доповнювати втручання задньою остеотомією п'яtkової кістки.

Дослідження виконано відповідно до принципів Гельсінської декларації. Протокол дослідження схвалено локальною етичною комісією установи, що брала участь у дослідженні. На проведення досліджень отримано інформовану згоду пацієнтів.

Ключові слова: дитячий церебральний параліч, п'яtkова стопа, діти.

Introduction

The heel foot in children with cerebral palsy is formed in 6% of cases [15,20,24,28]. The main reason for its occurrence is muscle imbalance due to dysfunction of the triceps femoris muscle [18,19,31,32]. The causes of muscle weakness include lengthening of its kinematic chain, which is aimed at eliminating the equinus position of the foot, bringing the fixation points closer together in flexion contractures of the knee joints and reducing the duration of the force contraction phase, which leads to functional muscle tissue deficiency [5,13].

Restoration of the triceps function is one of the main factors in deformity correction. It is proposed to shorten the Achilles tendon, tenodesis according to Westin, transplantation of the extensor muscles to the Achilles tendon [3,29,39,45].

At the same time, the authors note the disadvantages of the proposed treatment methods, which arise due to the lack of objective calculations of kinematic chain shortening and insufficient study of the processes occurring in muscles and tendons [2,9,14,30,37]. In the process of growth of children with cerebral palsy, the position and shape of bones in the middle and hind-quarters change under the influence of multidirectional forces, which leads to the formation of a stiff foot [1,11,21,25]. However, there is no analysis of the position and anatomy of the calcaneus, the ratio of its height and length, the architectonics of power lines, Kite and Bohler's angles.

This has led to the development of a large number of methods for surgical correction of these deformities [5,7,8,10,16,17]. For example, the use of anterior or posterior calcaneal osteotomy, tricuspid and tibiofemoral arthrodesis is proposed [13,18,22,38]. However, there are no specific indications for their performance.

Thus, the analysis of the literature shows the need for a detailed study of issues related to changes in the anatomy and function of the foot flexor muscles and calca-

neus and the determination of indications for optimal methods of correction of the heel foot.

The purpose of the research – to study the anatomical and functional changes in the calf muscle and bones in children with heel foot to determine the optimal methods of diagnosis and correction of deformity.

Materials and methods of the study

We analysed the results obtained during the treatment of 14 patients aged 11 to 17 years with cerebral palsy complicated by heel foot formation. Each foot was considered as a separate clinical case. All children had bilateral foot deformities.

After the examination, it was found that the heel foot was formed in children after achilloplasty, Stryer and Vulpius operations and as a result of knee joint contracture in patients with cerebral palsy.

In order to study the results of the application of certain methods of heel foot correction, 2 groups were identified. The main group (12 cases), in which posterior calcaneal osteotomy with Achilles tendon plasty and transposition of the tibialis anterior tendon was performed (Bohler, Kite angle $> 35^\circ$, Danilov angle $> 40^\circ$). The comparative group (16 cases), in which Achilles tendon shortening and transposition of the tibialis anterior tendon were performed. Taking into account the difference in radiological parameters of Bohler, Kite, Danilov angles, the comparison group was divided into 2 subgroups: the subgroup A – 6 cases (Bohler, Kite angle $< 35^\circ$, Danilov angle $< 40^\circ$); the subgroup B – 10 cases (Bohler, Kite angle $> 35^\circ$, Danilov angle $> 40^\circ$).

When conducting podometric and radiological studies, it was found that the indicators depend on the age of children, which is confirmed by Boyle MJ, Walker CG Shoukry FA [2,39]. Therefore, to determine the reference values, an anthropometric study was conducted in 15 children aged 12–17 years without pathology of the central nervous system.

Inclusion criteria: rigid heel foot in children with cerebral palsy.

Exclusion criteria: heel foot in flaccid paralysis caused by congenital pathology or spinal cord injury.

The clinical examination included the determination of active and passive movements in the joints of the foot. Motor skills were assessed according to the Gross Motor Function Classification System (GMFCS).

Foot condition before surgical treatment according to the American Orthopaedic Foot Association Scale (AOFAS).

The load on different parts of the foot was studied using baropodometry. For this purpose, the longitudinal load coefficients were determined [6].

Ultrasound diagnostics (US) was used to study the ratio of the length of the muscle and tendon parts of the calf muscle.

In order to study the main force vectors directed to the anterior and posterior compartments of the calcaneus, the lines along the internal and external trabecular meshes were studied (Fig. 1).

The radiological Bohler angle in the lateral projection, which reflects the position of the calcaneus, was investigated. The angle is formed by the intersection of a line drawn through the apices of the anterior process and the posterior calcaneal facet and a line drawn through the apices of the calcaneal tubercle from the posterior calcaneal facet (Fig. 2).

We also measured the Kite angle in the lateral projection, which is formed by the intersection of the longitudinal axes of the talus and calcaneus (Fig. 3).

The digital values were statistically processed to determine $M \pm m$, the coefficient of reliability according to Student's criteria. The significance was set at the level of $p < 0.5 - 0.05$.

The study was conducted in accordance with the principles of the Declaration of Helsinki. The study protocol was approved by the local ethics committees of all institutions participating in the study. Informed consent was obtained from the patients.

Results of the study and discussion

To study the ratio of the length of the muscle and tendon parts of the calf muscle, ultrasound was used ac-

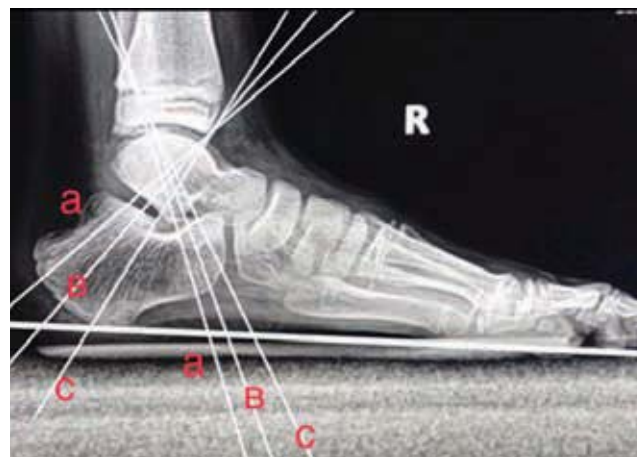


Fig. 1. Radiograph of the foot in lateral view. Trabecular lines of the anterior and posterior calcaneus: a – posterior; b – central; c – anterior

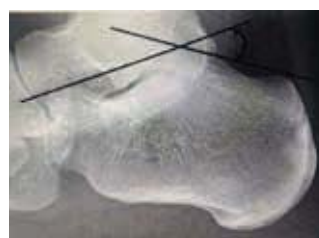

Fig. 2. Radiograph of the foot in lateral projection. Determination of the Bohler angle

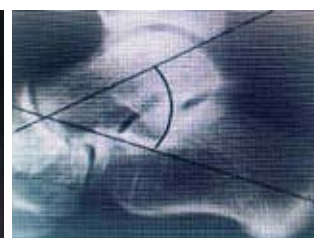


Fig. 3. Radiograph of the foot in lateral view. Determination of the Kite angle

cording to the method of A. Kruse [25]. In order to optimise the examination methodology, the authors developed a manual method for assessing the ratio of tendon to muscle, which consists in measuring the length of the entire muscle from the heel tubercle to the inner ankle of the femur (the point of attachment of the medial head). Next, the place where the muscle passes into the tendon part was marked. The distance from the given point to the heel tubercle was measured. In this case, the foot was at an angle of 90° to the lower leg. On the basis of the obtained digital values, the ratio of the tendon part to the muscle part (C) was determined in percentage according to the formula: $C = BN \times 100 / AB$, where A is the distance from the attachment point of the medial head to the inner ankle of the femur; B is the distance from the attachment point of the gastrocnemius tendon to the calcaneus; (the distance was measured in

Table 1

Comparison of reference and mean values of the length of the tendon part of *m. gastrocnemius* in relation to the muscle part depending on the cause of heel foot formation (%)

Achilloplasty n=9		Surgery according to Strayr, Vulpius, transverse section of the tendon-aponeurotic part of the calf n=12		Flexion contracture of the knee joint n=7	
Reference value	Deformation	Reference value	Deformation	Reference value	Deformation
27.3±2.8	35.3±1.7	27.3±2.8	47.3±1.8	27.3±2.8	46.4±2.3

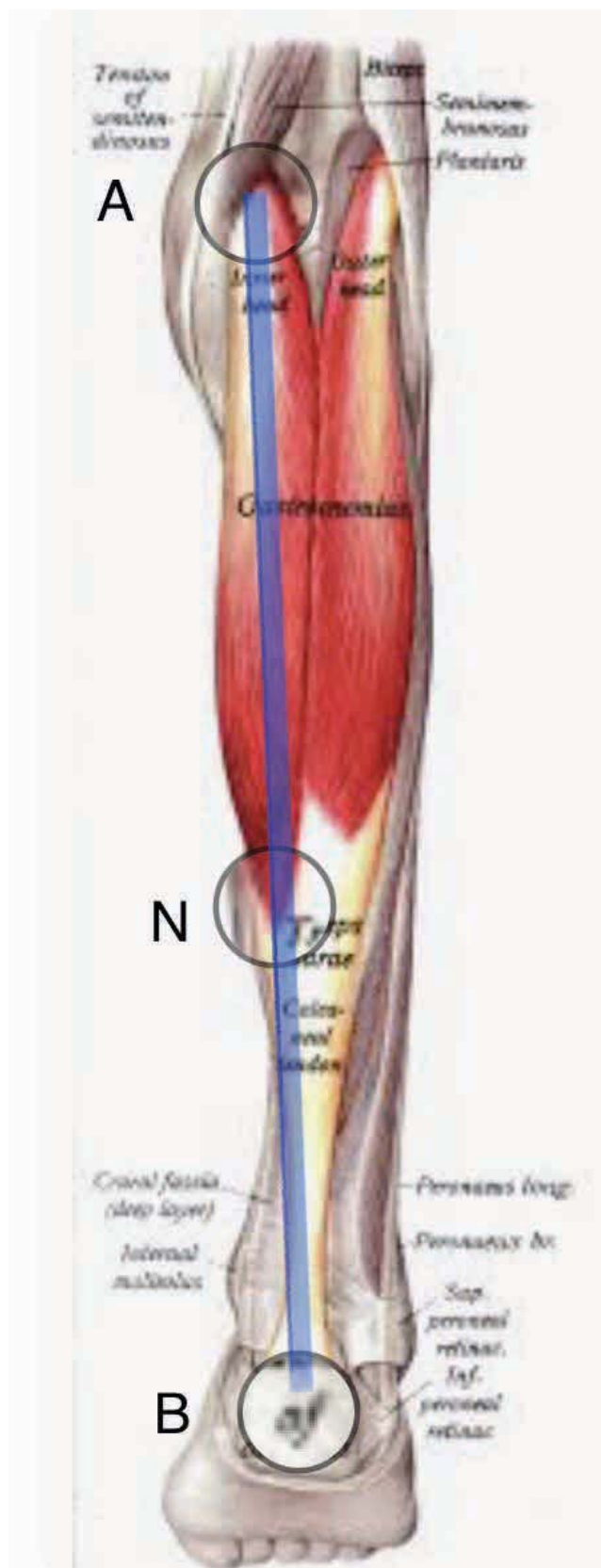


Fig. 4. Determination of the ratio of the length of the tendon part to the muscle part of the gastrocnemius muscle: A – the point of attachment of the medial head to the inner ankle of the femur; B – the point of attachment of the gastrocnemius tendon to the calcaneus; N – the point of transition of the gastrocnemius muscle to the tendon part

centimetres). N – the point of transition of the gastrocnemius muscle to the tendon part (Fig. 4).

In order to substantiate the reliability of the manual method of measuring the ratio of the length of the tendon and muscle parts of the calf muscle, a comparative assessment of the indicators using ultrasound was performed. Therefore, to determine the reference values, an anthropometric study was conducted in 15 children aged 12–17 years without pathology of the central nervous system. The reference values of the ratio were $27.3 \pm 2.8\%$.

The data indicated the absence of a large discrepancy depending on the method of examination, which indicates the reliability of the manual technique. The dependence of indicators of the ratio of the length of the muscle and tendon parts of the calf muscle depending on the cause of the deformity formation was established (Table 1).

The analysis of the ratio of the tendon and muscle parts of the calf muscle showed that the lengthening of the Achilles tendon was the greatest after the previous operations: Strayr, Vulpius, and transverse section of the tendinous-aponeurotic stretch of the calf muscle. This phenomenon can be explained by the uncontrolled lengthening of the tendinous-aponeurotic part of the calf muscle during its crossing and fibrous degeneration of the foot flexor muscle tissue.

A significant lengthening of the Achilles tendon is also noted in flexion contractures of the knee joints, as the muscle retracts. And in the long clinical course of the disease, degenerative and dystrophic changes in muscle tissue occur, which, when combined, cause muscle shortening and relative lengthening of the tendon. This position is confirmed by the direct dependence of the degree of relative lengthening of the tendon and the size of the contracture angle in the knee joint (Fig. 5).

Taking into account the results obtained, it should be noted that in the presence of flexion contractures of the knee joints and heel foot, it is necessary to first eliminate the contracture of the knee joints (simultaneously or in a separate stage), and then correct the foot. If this principle is not followed, an unsatisfactory result is possible due to inadequate modelling of the length of the kinematic chain of the muscle part and Achilles tendon, which can lead to the formation of an equinus foot setup.

In the process of studying foot pathology, the Bohler and Kite angles are usually assessed, but they do not take into account the biomechanics of the load on the calcaneal tuberosity. In order to assess in detail the deformation of the calcaneus as a result of changes in the position of the calcaneal tubercle, the authors developed a method for determining the angle formed by the intersection of the line drawn through the apexes of the anterior

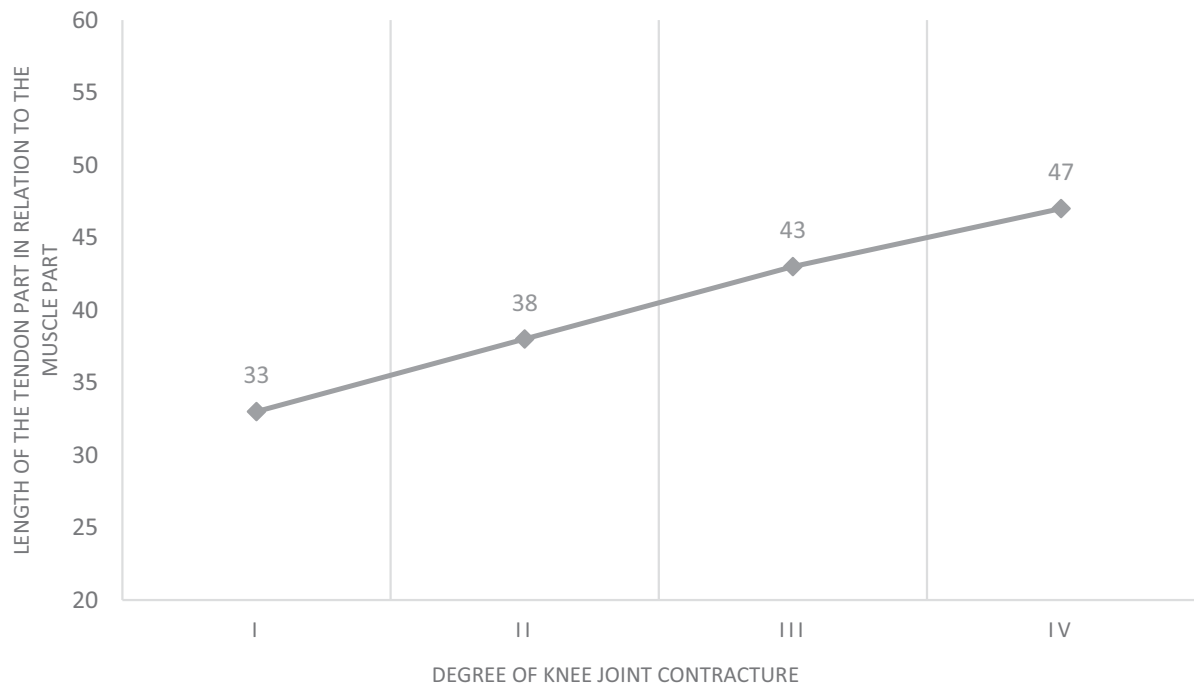


Fig. 5. Dependence of the relative length of the tendon part in relation to the muscle part of the *m. gastrocnemius* on the degree of knee joint contracture

process and the posterior facet of the calcaneus and the line drawn between the sustentaculum tali and the centre of the calcaneus (hereinafter referred to as the Danilov angle; Fig. 6).

Radiological data in the examination of patients with heel foot indicate that the greatest changes occur in the Bohler, Kite, Danilov angles (Table 2).

In the course of the study, congruence disorders in the joints of the hindfoot and changes in the configuration of the calcaneus due to the progression of pathology were found. The Kite and Bohler angles in heel foot almost do not differ from the reference values and

provide an incomplete picture of changes in the hind-foot. Also, their use is ineffective in assessing changes in the shape and configuration of the calcaneus, unlike the Danilov angle.

We have noted a decrease in the angles between the trabecular lines of the calcaneus, which correlate with the increasing values of the Bohler and Danilov angles (Fig. 7).

The table shows the angles between the trabecular lines, which decrease in heeled feet due to changes in the position of the heel bone and the restructuring of the trabecular meshwork (Table 3).

Table 2

Average values of radiological parameters before surgery (in degrees)

Groups	Kite angle		Bohler angle		Danilov angle	
	reference value	heel foot	reference value	heel foot	reference value	heel foot
Main (n=12), M±m	32.5±4.0	36.4±3.7	32.0±2.7	35.5±3.8	35.0±2.8	43.1±2.5
Comparative A (n=6), M±m	32.5±4.0	34.3±2.4	32.0±2.7	34.3±3.4	35.0±2.8	38.4±2.7
Comparative B, (n=10), M±m	32.5±4.0	37.1±2.8	32.0±2.7	37.5±2.7	35.0±2.8	43.4±2.9

Table 3

The average value of the trabecular line angles of the calcaneus before surgery (in degrees)

Groups	Angle between the front lines		Angle between centre lines		Angle between the back lines	
	reference value	heel foot	reference value	heel foot	reference value	heel foot
Main (n=12), M±m	93.8±7.8	68.3±1.7	85.2±5.6	61.3±2.1	86.4±5.6	61.2±1.9
Comparative A (n=6), M±m	93.8±7.8	75.4±2.4	85.2±5.6	73.4±1.8	88.4±5.6	76.4±1.7
Comparative B, (n=10), M±m	93.8±7.8	67.4±1.9	85.2±5.6	62.2±2.3	88.4±5.6	61.5±2.2

Оригінальні дослідження. Ортопедія

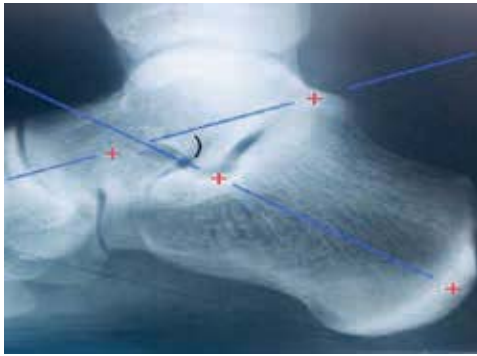

Fig. 6. Radiograph of the foot in lateral projection. Determination of Danilov angle ($N \leq 35^\circ$)

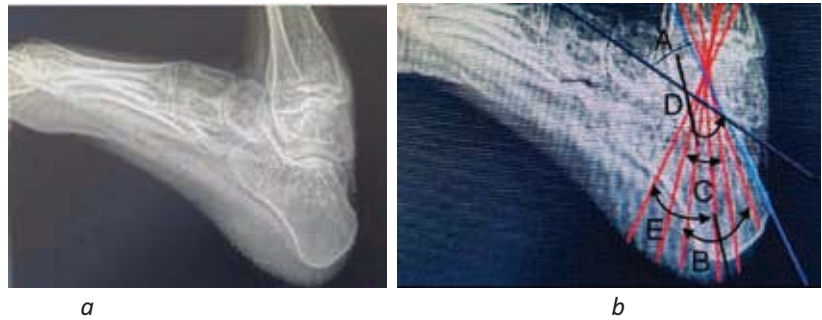

Fig. 7. Radiological images of the foot in lateral view. Bohler, Danilov angles (a – normal; b – with heel foot): A – Bohler angle; B – angle between the posterior trabecular lines; C – angle between the central trabecular lines, D – Danilov angle; E – angle between the anterior trabecular lines

The direction of the power lines in heel foot indicates a change in the load on the hindfoot with the fulcrum on the calcaneus. Conditions are created when, in the absence of traction of the hindfoot in the proximal direction, the load axis passing through the calcaneus changes.

Under normal conditions, the load is uniform on the anterior, middle and calcaneal tuberosity with the transfer of force to the talus neck and its transfer to a horizontal position. In the presence of a heel foot, the angle and distance between the trabecular lines of the anterior and posterior calcaneus decreases, indicating that the load axis is transferred mainly to the calcaneus, which changes position in the main direction. Thus, the relationship between the Bohler angle and the position of the calcaneus changes. Indicators of the angle between the anterior and posterior compartments of the calcaneus are more characteristic of changes in the anatomy of the calcaneus. Therefore, a prerequisite for creating optimal biomechanical conditions is to correct the shape of the calcaneus in accordance with its normal anatomical parameters. To confirm this position, the functional state of the foot and motor motor skills in patients of the main and comparison groups were studied (Table 4).

The results of the motor motor assessment, which was carried out in groups according to the Gross Motor Function Classification System (GMFCS), were as follows: the comparison group A – 4 cases of level II,

2 cases of level III; the comparison group B – 6 cases of level III, 4 cases of level IV; the main group – 6 cases of level III, 6 cases of level IV.

In order to determine the length by which the kinematic chain should be shortened, the ratio of the length of the tendon part to the muscle part of the calf muscle was determined. Surgical access was started with a 6–7 cm long incision along the lateral edge in the projection of the Achilles tendon, then the place where the calf muscle transitions to the tendon part was identified. The distance from the marked area to the point of attachment of the Achilles tendon to the calcaneus was measured. The tendon was mobilised for 5 cm and crossed transversely. The proximal segment of the tendon was moved along the distal segment to a distance that corresponded to the difference in the ratio between the standard values in each case. If the normal values correspond to 27%, and the patient has 45%, then the desired number is 18% (the distance by which the kinematic chain should be shortened). The criterion for sufficient correction is the position of the foot in the ankle joint 100° - 110° . Lower values indicate an insufficient correction of the tendon length due to miscalculation or technical error. The ends of the tendon were stabilised with sutures.

Tendon transplantation of the tibialis anterior muscle was performed by isolating, transecting and mobilising it at the site of attachment of the medial sphenoid bone and the base of the first metatarsal bone. Then, with the

Table 4

Indicators of the functional state of the foot and lower leg before surgery

Indicators	Reference value	Comparative A n=6 M±m	Comparative B n=10 M±m	Main n=12 M±m
Longitudinal load factor	0.5–1.0	3.1±0.8	4.2±0.7	4.4±0.4
Foot condition according to the AOFAS scale (in points)	100	52.3±5.2	40.1±4.1	38.7±3.5
Dependence of the length of the tendon part in relation to the muscle part m. Gastrocnemius (%)	27.0	38.3	44.8	45.2

help of additional incisions of 1.5–2 cm, the tendon was isolated to the border of the lower and middle third of the anterior surface of the tibia and was passed through the intertibial space, where it was fixed at the site of attachment of the Achilles tendon to the calcaneal tubercle. For better stabilisation, a cleft was formed in the Achilles tendon, into which the transplanted tendon was inserted and fixed. Osteotomy of the calcaneus was performed from an incision along its lateral surface. The distal bone fragment was displaced in the proximal and, if necessary, in the medial direction to the required amount and fixed with two screw-tapped pins. In the presence of a valgus foot deviation, the calcaneus was corrected in two projections (Fig. 8).

Postoperative management of patients: the foot was immobilised with a plaster cast of the «Boot» type for 5–6 weeks, depending on the patient's age. Subsequent immobilisation of the foot was carried out with a dynamic orthosis for 8–12 months in combination with physiotherapy until its full function was restored (Fig. 9).

The analysis of radiological examinations after surgery shows an increase in the Kite, Bohler, Danilov angles (Table 5).

Indicators show that soft tissue surgery, without correcting the shape of the calcaneus, is effective in moderate calcaneal deformity (Danilov angle $<40^\circ$).

After the surgical treatment, a change in the load on the hindfoot was achieved. As a result, the trabecular meshwork of the calcaneus was restructured, as evidenced by changes in the angles of the trabecular lines (Table 6).

The trabecular line angles also indicate that soft tissue surgery, without correcting the shape of the calcaneus, was effective at angles: between the anterior lines $>70^\circ$; between the central and posterior lines $>65^\circ$.

In the comparative group B, at higher radiological angles (Kite, Bohler $\geq 35^\circ$, Danilov $\geq 40^\circ$), the longitudinal load coefficient increases, which shows insufficient recovery of the main biomechanical parameters (most of the load is carried out on the hindfoot). The foot assessment according to the AOFAS scale indicates poor functional adaptation of patients (Table 7).

Table 5

Comparison of radiological angles before and after surgery (in degrees)

Groups	Kite angle M±m		Bohler angle M±m		Danilov angle M±m	
	before the operation	after the operation	before the operation	after the operation	before the operation	after the operation
Main (n=12), M±m	36.4±3.7	33.1±2.6	35.5±3.8	32.3±2.6	43.1±2.5	36.4±1.8
Comparative A (n=6), M±m	34.3±2.4	32.4±2.9	34.3±3.4	31.2±3.8	38.4±2.7	35.1±1.4
Comparative B, (n=10), M±m	37.1±2.8	36.8±3.4	37.5±2.7	36.4±2.5	43.4±2.9	42.1±1.2

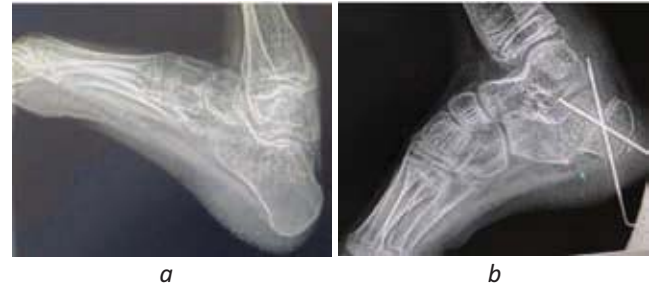

Fig. 8. X-ray of the foot in lateral view: a – before surgical treatment; b – after calcaneal osteotomy. Patient K. is 14 years old. Diagnosis: cerebral palsy, heel foot

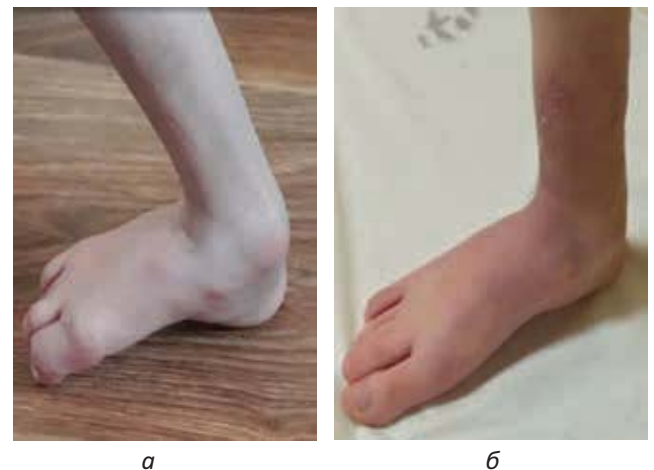

Fig. 9. Patient K. 14 years old. Diagnosis: cerebral palsy, heel foot with flexion contracture of the toes. Photo of the foot: a – before surgical treatment; b – 12 months after surgical treatment

Insufficient symptomatic and functional correction of the deformity negatively affects motor skills. Thus, according to the GMFCS scale, level I is achieved only in the main group and in the comparison A.

In the world literature, there are mixed views on the causes of heel foot. Thus, some authors believe that excessive lengthening of the triceps kinematic chain after correction of the equinus foot is the main cause of the formation of heel foot [12,18,29,22,35]. The greatest elongation, in our opinion, is noted in the transverse section of the aponeurotic stretch of the gastrocnemius muscle, and the diastasis of the section is formed by extending the foot in the ankle joint more than 90° .

Оригінальні дослідження. Ортопедія

Table 6

Comparison of heel trabecular line angles before and after surgery (in degrees)

Groups	Angle between the front lines M±m		Angle between centre lines M±m		Angle between the back lines M±m	
	before the operation	after the operation	before the operation	after the operation	before the operation	after the operation
Main n=12	68.3±1.7	73.1±1.6	61.3±2.1	67.4±2.2	61.2±1.9	68.1±1.6
Comparative A n=6	75.4±2.4	80.3±1.7	73.4±1.8	80.2±2.3	76.4±1.7	81.3±1.3
Comparative B n=10	67.4±1.9	68.5±1.8	62.2±2.3	64.2±2.4	61.5±2.2	63.6±2.1

Table 7

Comparison of the functional state of the foot and lower leg before and after surgery

Indicators	Comparative group A n=6 M±m		Comparative group B n=10 M±m		Main n=12 M±m	
	before the operation	after the operation	before the operation	after the operation	before the operation	after the operation
Longitudinal load factor	3.1±0.8	1.2±0.5	4.2±0.7	2.2±0.3	4.4±0.4	1.3±0.2
Foot condition according to the AOFAS scale (in points)	52.3±5.2	62.0±1.0	40.1±4.1	45.1±2.0	38.7±3.5	60.0±1.0
Dependence of the length of the tendon part in relation to the muscle part m. Gastrocnemius (%)	38.3±1.2	29.3±1.4	44.8±1.2	37.8±1.4	45.2±1.1	30.5±1.3

It should be noted that Strayr's proposal is a U-shaped cut of the gastrocnemius muscle at the border of the tendinous-muscular part with 2–3 mm of aponeurotic bands preserved along its edges [42]. However, with insufficient or excessive length of the lateral parts of the aponeurosis, an inadequate lengthening of the gastrocnemius muscle chain is created with insufficient correction of the equinus contracture of the foot or the formation of a heel deformity. Some researchers [43] suggest a transverse section of the tendon-aponeurotic stretch with fixation in a given position, but this creates a high risk of excessive chain lengthening.

The analysis of observations of patients with heel foot who had an increase in the kinematic chain showed that the smallest lengthening of the tendon relative to the muscle part was noted in patients after achilloplasty. This surgical intervention is not widely used today. To prevent complications, the authors propose a mathematical calculation of the amount of lengthening of the Achilles tendon [2,41].

After analysing the results of treatment of patients with different pathogenetic causes of heel foot, it should be noted that the length of the tendon part relative to the gastrocnemius muscle is influenced by factors not only by excessive lengthening of the kinematic chain, but also by the degree of retraction of the muscle itself and its degenerative and dystrophic changes observed in flexion

contracture of the knee joint. Thus, it can be argued that heel foot as a consequence of functional insufficiency of the triceps femoris muscle is multifactorial in nature. Correction of the equinus foot does not take into account the degree of spasticity, the position of the foot in the ankle joint after crossing the tendon-muscle stretch of the calf muscle, as well as the duration of postoperative foot fixation, which leads to the formation of heel foot. When restoring the function of the triceps muscle using the manual method of assessing the ratio of the tendon to muscle part, an adequate correction of the kinematic chain is achieved. This makes it possible to restore the structure and function of the muscle.

Tibialis anterior tendon transplantation is aimed at two things: elimination of the pathological effect of its retraction and compensation for the functional deficiency of the triceps tendon.

When analysing radiographs of the foot in children aged 6 to 12 years, some authors found that the values of the main 11 clinical useful angles change with age. To evaluate the main radiological parameters, it is necessary to take into account the age of patients, as well as anthropometric data [23,26,33]. The analysis of the radiological parameters of the foot in children aged 12–17 years shows that the range of differences in the indicators is within 20°-25°. Given the particularly large differences in the Kite and Bohler angles, the study presents its own

standard values. Also, these angles do not take into account changes in the shape and structure of the calcaneus during the formation of pathology. Therefore, we proposed measuring the angles between the anterior, middle and posterior trabecular lines, as well as the Danilov angle.

K. Bo. Park and co-workers [36] proved that patients with myelodysplasia heel foot had a disturbance in the shape of the foot bones, mainly of the middle and posterior compartments. Our own observations have shown that sufficient correction of the deformity by shortening the Achilles tendon and transplanting the tibialis anterior muscle to the site of fixation of the Achilles tendon to the calcaneus is possible at a Bohler angle of $<35^\circ$ and a Danilov angle of $<40^\circ$. At higher values, reshaping of the calcaneus by means of a posterior osteotomy is necessary.

D. Evans [13] addressed the issue of heel foot treatment along with muscle transplantation by anterior calcaneal osteotomy. In our opinion, such an intervention allows for correction of only the valgus deviation of the calcaneus in the horizontal plane, without the possibility of eliminating the deformity in the frontal plane. Therefore, we believe that in the presence of a valgus foot deviation, correction of the calcaneus should take place in two projections.

M.A. Smolle [40] believes that the use of the AOFAS scale in children does not provide sufficient data on the effectiveness of treatment of foot deformities. In our opinion, the assessment of the foot condition according to the AOFAS scale should be combined with the assessment of motor skills according to the Gross Motor Function Classification System (GMFCS), which makes it possible to achieve appropriate results of surgical treatment.

Conclusions

The study of anatomical and functional changes in the gastrocnemius muscle and bones in children with cerebral palsy proves the need to correct the length of the kinematic chain of the gastrocnemius muscle. It is necessary to calculate the ratio of its muscle and tendon parts according to physiological indicators. The study of radiological parameters of Bohler, Kite, Danilov angles in children with heel foot showed their increase. The results of surgical correction in groups of patients with Achilles tendon shortening and transplantation of the tibialis anterior tendon to the calcaneus tubercle showed effectiveness at Bohler, Kite angle $<35^\circ$ and Danilov angle $<40^\circ$. At higher values, surgical intervention should be supplemented with a posterior calcaneal osteotomy with proximal and, if necessary, medial displacement of the distal fragment. The study of the architec-

tonics of the calcaneal power lines showed a decrease in the angles between the trabecular lines of the central and hindfoot, which correlate with the Bohler and Danilov angles, indicating an increase in the vertical load on the hindfoot and changes in the position of the calcaneal tubercle. This is also an indication for calcaneal osteotomy. Baropodometry, GFMCS and AOFAS scores allow for a high degree of reliability in assessing the effectiveness of treatment of foot deformities in children with cerebral palsy.

No conflict of interests was declared by the authors.

References/Література

- Banta J. (1981). Anterior tibial transfer to the os calcis with Achilles tenodesis for calcaneal deformity in myelomeningocele. *J Pediatr Orthop.* 1: 125–130. doi: 10.1097/01241398-198110000-00001.
- Boyle MJ, Walker CG, Crawford HA. (2011). The paediatric Bohler's angle and crucial angle of Gissane: a case series. *J Orthop Surg Res.* 6 (2): 1–5. doi: 10.1186/1749-799X-6-2.
- Chan M, Khan S. (2019). Ilizarov reconstruction of chronic bilateral calcaneovalgus deformities. *Chin J Traumatol.* 22 (4): 202–206.
- Cho BC, Lee IH, Chung CY, Sung KH, Lee KM, Kwon SS et al. (2018). Undercorrection of planovalgus deformity after calcaneal lengthening in patients with cerebral palsy. *J Pediatr Orthop B.* 27 (3): 206–213.
- Conti M, Garfinke J, Kunas G, Deland J, Ellis S. (2019). Postoperative Medial Cuneiform Position Correlation With Patient-Reported Outcomes Following Cotton Osteotomy for Reconstruction of the Stage II Adult-Acquired Flatfoot Deformity. *Foot Ankle Int.* 40 (5): 491–498.
- Danilov O, Shulga A, Gorelik V. (2021). The effectiveness of treatment in children with rigid flatfeet and dysfunction of the posterior tibial tendon. *Georgian Med News.* 320: 46–52.
- Danilov OA, Gorelik VV, Shulga OV. (2023). Analysis of the effectiveness of methods of correction of pronation deformities of the feet in children with cerebral palsy. *Paediatric Surgery (Ukraine).* 2 (79): 50–57. doi: 10.15574/PS.2023.79.50.
- Danylyov AA, Gorelik VV, Shulga AV, Yachna KV. (2023). Pathologic external tibial torsion as one of the causes of knee joint dysfunction and formation of pronation deformity in children with cerebral palsy. *Paediatric Surgery (Ukraine).* 1 (78): 110–118. doi: 10.15574/PS.2023.78.110.
- Dauids J. (2010). The foot and ankle in cerebral palsy. *Orthop Clin.* 41 (4): 579–593. doi: 10.1016/j.ocl.2010.06.002.
- Dawe J, Davis J. (2011). Anatomy and biomechanics of the foot and ankle. *Orthopaedics and Trauma.* 25; 4: 279–285. <https://doi.org/10.1016/j.mporth.2011.02.004>.
- Dias L. (1985). Valgus deformity of the ankle joint: pathogenesis of fibular shortening. *J Pediatr Orthop.* 5 (2): 176–180.
- Dillin W. (1983). Calcaneus deformity in cerebral palsy. *Foot Ankle.* 4 (3): 167–170.
- Evans D. (1975). Calcaneo-valgus deformity. *J Bone Joint Surg Br.* 57 (3): 270–278.
- Frazer H. (2018). *Biomechanics of the Foot and Ankle* Published online by Cambridge University Press. 2: 22–43. <https://doi.org/10.1017/9781108292399.003>.
- Fulford G. (1990). Surgical management of ankle and foot deformities in cerebral palsy. *Clin Orthop Relat Res.* 253: 55–61.
- Haendlmayer KT, Harris NJ. (2009). Flatfoot deformity: an overview. *Orthop Trauma.* 23 (6): 395–403. URL: <https://doi.org/10.1016/j.mporth.2009.09.006>.
- Hawke F, Rome K, Evans AM. (2016). The relationship between foot posture, body mass, age and ankle, lower-limb and whole-

Оригінальні дослідження. Ортопедія

- body flexibility in healthy children aged 7 to 15 years. *J Foot Ankle Res.* 9: 14. URL: <https://doi.org/10.1186/s13047-016-0144-7>.
18. Julieanne P, Miller F. (2013). Overview of foot deformity management in children with cerebral palsy. *J Child Orthop.* 7 (5): 373–377.
 19. Kalkman BM, Bar-On L, Cenni F, Maganaris CN, Bass A, Holmes G et al. (2017). Achilles tendon moment arm length is smaller in children with cerebral palsy than in typically developing children. *J Biomech.* 56: 48–54.
 20. Kedem P. (2015). Foot deformities in children with cerebral palsy. *Curr Opin Pediatr.* 27 (1): 67–74.
 21. Keener BJ. (2005). The anatomy of the calcaneus and surrounding structure. *Foot Ankle Clin.* 10; 3: 413–424. doi: 10.1016/j.fcl.2005.04.003.
 22. Kitaoka H, Alexander I, Adelaar R, Nunley J, Myerson M, Sanders M. (1994). Clinical rating systems for the ankle-hindfoot, midfoot, hallux, and lesser toes. *Foot Ankle Int.* 15 (7): 349–353. doi: 10.1177/107110079401500701.
 23. Korzh M, Prozorovsky D, Romanenko K. (2009). Current radiographic anatomical parameters in the diagnosis of transverse spreading deformity of the forefoot. *Trauma.* 4: 444–449.
 24. Kozhevnikov O, Kralina S, Priorov N, Gribova I, Ivanov A. (2019). Pes calcaneus deformity in children and methods of surgical correction. *Pediatric Traumatology Orthopaedics and Reconstructive Surgery.* 7 (2): 69–78.
 25. Kruse A, Schranz C, Svehlik M. (2018). Muscle and tendon morphology alterations in children and adolescents with mild forms of spastic cerebral palsy. *BMC Pediatrics.* 18: 156. <https://doi.org/10.1186/s12887-018-1129-4>.
 26. Lai C, Wang T, Chang C, Pao J, Fang H, Chang C, Lin S, Lan T. (2021). Calcaneal lengthening using ipsilateral fibula autograft in the treatment of symptomatic pes valgus in adolescents. *BMC Musculoskeletal Disorders.* 22: 977.
 27. Lee SY, Chung CY, Park MS, Sung KH, Ahmed S, Koo S et al. (2018). Radiographic measurements associated with the natural progression of the hallux Valgus during at least 2 years of follow-up. *Foot Ankle Int.* 39 (4): 463–470.
 28. Makin M. (1966). Translocation of the peroneus longus in the treatment of paralytic pes calcaneus. A follow-up study of thirty-three cases. *J Bone Joint Surg Am.* 48 (8): 1541–1547.
 29. Mani SB, Deland JT. (2014). Lateral column lengthening and how to achieve good correction [Internet]. *Tech Foot Ankle.* 13 (1): 23–28. <https://doi.org/10.1097/BTF.0000000000000003>.
 30. Mankey MG. (2003). A classification of severity with an analysis of causative problems related to the tipe of treatment. *Foot Ankle Clin.* 8 (3): 461–71. [https://doi.org/10.1016/s1083-7515\(03\)00124-4](https://doi.org/10.1016/s1083-7515(03)00124-4).
 31. Mayich DJ, Novak A, Vena D, Daniels TR, Brodsky JW. (2014). Gait analysis in orthopedic foot and ankle surgery – topical review, part I: principles and uses of gait analysis. *Foot Ankle Int.* 35 (1): 80–90. <https://doi.org/10.1177/1071100713508394>.
 32. Min J, Kwon S, Sung K, Kyoung M, Chin Y, Moon S. (2020). Progression of planovalgus deformity in patients with cerebral palsy. *BMC Musculoskeletal disorders.* 21: 141. <https://doi.org/10.1186/s12891-020-3149-0>.
 33. Muir D. (2005). Tibiotalocalcaneal arthrodesis for severe calcaneovalgus deformity in cerebral palsy. *J Pediatr Orthop.* 25 (5): 651–656.
 34. Ozyalvac O, Akpınar E, Bayhan A. (2020). A Formula to Predict the Magnitude of Achilles Tendon Lengthening Required to Correct Equinus Deformity. *Med Princ Pract.* 29 (1): 75–79.
 35. Pandey A, Pandey S, Prasad V. (1989). Calcaneal osteotomy and tendon sling for the management of calcaneus deformity. *Free Online AOFAS Ankle-Hindfoot Scale Calculator – OrthoTool-Kit.* *J Bone Joint Surg Am.* 71 (8): 1192–1198.
 36. Park KB, Park HW, Joo SY, Kim HW. (2008, Oct). Surgical treatment of calcaneal deformity in a select group of patients with myelomeningocele. *J Bone Joint Surg Am.* 90 (10): 2149–2159. doi: 10.2106/JBJS.G.00729. PMID: 18829913.
 37. Patrícia M, Fucs M. (2007). Celso Svartman Results in the treatment of paralytic calcaneus-valgus feet with the Westin technique. *Sidney de Carvalho Fabricio Int Orthop.* 31 (4): 555–560. doi: 10.1007/s00264-006-0214-8.
 38. Resende RI, Pinheiro LSP, Ocarino JM. (2019). Effects of foot pronation on the lower limb sagittal plane biomechanics during gait. *Gait & Posture.* 68: 130–135.
 39. Shoukry FA, Aref K, Sabry A. (2012). Evaluation of the normal calcaneal angles in Egyptian population. *Alexandria Journal of Medicine.* 48 (2): 91–97.
 40. Smolle M. (2022). Biomechanical Basis for Treatment of Pediatric Foot Deformities Part II: Pathomechanics of Common Foot Deformities. *Home Archives Foot & Ankle.* 4; 2.
 41. Stott N, Perry J. (1996). Tibialis anterior transfer for calcaneal deformity: a postoperative gait analysis. *J Pediatr Orthop.* 16 (6): 792–798. doi: 10.1097/00004694-199611000-00017.
 42. Strayer LM Jr. (1950). Recession of the gastrocnemius. An Operation to Relieve Spastic Contracture of the Calf Muscles. *The Journal of Bone Joint Surgery.* 32 (3): 671–676.
 43. Sung KH, Kwon SS, Park MS, Lee KM, Ahn J, Lee SY. (2019). Natural progression of radiographic indices in juvenile hallux valgus deformity. *Foot Ankle Surg.* 25 (3): 378–382.
 44. Wenz W. (2018). Complete tendon transfer and inverse Lambrinudi arthrodesis: preliminary results of a new technique for the treatment of paralytic pes calcaneus. *Foot Ankle Int.* 29 (7): 683–689. <https://doi.org/10.3113/FAI.2008.0683>.
 45. Westin G. (1998). The results of tenodesis of the tendo achillis to the fibula for paralytic pes calcaneus. *J Bone Joint Surg Am.* 70: 320–322.

Відомості про авторів:

Данилов Олександр Андрійович – д.мед.н., проф. каф. дитячої хірургії, анестезіології, ортопедії та травматології НУОЗ України імені П.Л. Шупика. Адреса: м. Київ, вул. Дорогожицька, 9. <https://orcid.org/0000-0002-4605-7032>.

Шульга Олександр Володимирович – Phd, асистент каф. дитячої хірургії, анестезіології, ортопедії та травматології НУОЗ України імені П.Л. Шупика. Адреса: м. Київ, вул. Дорогожицька, 9. <https://orcid.org/0000-0002-9962-2816>.

Стаття надійшла до редакції 17.07.2023 р., прийнята до друку 11.12.2023 р.