

Клінічний випадок

UDK 616.61-002-036.12-053.2

M. Szymanek–Szwed, K. Załęska–Oracka, J. Samotyjek, K. Jobs, B. Jurkiewicz

## Pyelonephritis Xanthogranulomatosa – case report (2 cases)

Centre of Postgraduate Medical Education, Dziekanów Leśny, Warsaw, Poland

PAEDIATRIC SURGERY.UKRAINE.2019.2(63):92-96; DOI 10.15574/PS.2019.63.92

Pyelonephritis xanthogranulomatosa is a very rare form of chronic kidney inflammation. Only a few hundred cases have been described in children. The cause of the disease is not fully understood, but it is strongly correlated with urolithiasis. The inflammatory process usually involves one kidney and is diffuse, rarely a form limited to the part of the parenchyma is seen. The most common symptoms are abdominal pain, fever, weight loss, lack of appetite. In imaging tests the kidney is enlarged, with a preserved shape, contains deposits in the calyx and pelvic system and numerous hypoechogenic changes indicating abscesses. The most frequently isolated pathogens are *E. coli* and *P. Mirabillis*. The authors present 2 cases treated in our center due to Pyelonephritis xanthogranulomatosa. In both cases a nephrectomy was performed.

**Key words:** children, chronic kidney inflammation, Pyelonephritis xanthogranulomatosa.

### Ксантогранулематозний пієлонефрит: 2 клінічні випадки

M. Szymanek–Szwed, K. Załęska–Oracka, J. Samotyjek, K. Jobs, B. Jurkiewicz

Centre of Postgraduate Medical Education, Dziekanów Leśny, Warsaw, Poland

Ксантогранулематозний пієлонефрит – це дуже рідкісна форма хронічного запалення нирок. Описано лише кілька сотень випадків цього захворювання у дітей. Причина захворювання до кінця не зрозуміла, але вона тісно пов'язана з сечокам'яною хворобою. Запальний процес зазвичай включає одну нирку і є дифузним, рідше спостерігається форма, що обмежена частиною паренхіми. Найбільш поширеними симптомами є біль у животі, лихоманка, втрата ваги, відсутність апетиту. При візуалізаційних дослідженнях видно, що нирка збільшена, не зміненої форми, присутні відкладення в чашечці і тазовій системі, а також численні гіпоехогенні зміни, що свідчать про абсцеси. Патогенами, що виділяють найчастіше, є *E. coli* та *P. mirabillis*. Автори розглядають два випадки лікування ксантогранулематозного пієлонефриту в нашому центрі. В обох випадках було проведено нефрэктомію.

**Ключові слова:** діти, хронічне запалення нирок, ксантогранулематозний пієлонефрит.

### Ксантогранулематозный пиелонефрит: 2 клинических случая

M. Szymanek–Szwed, K. Załęska–Oracka, J. Samotyjek, K. Jobs, B. Jurkiewicz

Centre of Postgraduate Medical Education, Dziekanów Leśny, Warsaw, Poland

Ксантогранулематозный пиелонефрит – это очень редкая форма хронического воспаления почек. Описаны только несколько сотен случаев этого заболевания у детей. Причина заболевания до конца непонятна, но она тесно связана с мочекаменной болезнью. Воспалительный процесс обычно включает одну почку и является диффузным, реже наблюдается форма, ограниченная частью паренхимы. Наиболее распространенными симптомами являются боль в животе, лихорадка, потеря веса, отсутствие аппетита. При визуализированных исследованиях видно, что почка увеличена, не измененной формы, присутствуют отложения в чашечке и тазовой системе, а также многочисленные гипоехогенные изменения, свидетельствующие об абсцессах. Наиболее часто выделяемыми патогенами являются *E. coli* и *P. mirabillis*. Авторы рассматривают два случая лечения ксантогранулематозного пиелонефрита в нашем центре. В обоих случаях была проведена нефрэктомия.

**Ключевые слова:** дети, хроническое воспаление почек, ксантогранулематозный пиелонефрит.

### Introduction

Pyelonephritis xanthogranulomatosa is a very rare form of chronic kidney inflammation. It usually affects people between 40 and 60 years of age, only a few hundred cases are described in children [4,5]. The cause of the disease is not fully understood; however, it often co-exists with urolithiasis. Other suggested causes include prolonged antibiotic therapy with associated disorders

in urinary outflow and infection, dyslipidemia, dysfunctional lymphatic drainage, and renal ischemia [2]. The most frequently isolated pathogens in cultured urine are *E. coli* and *P. mirabilis* [2]. The inflammatory process usually involves one kidney and is diffuse, rarely has the form limited to the part of the parenchyma. The most common symptoms are abdominal pain, fever, weight loss, and lack of appetite. During physical examination,

pain in one side of the abdomen and abdominal tumour are most often found [1–4].

In additional tests high inflammatory markers (WBC, CRP, PCT) are found, anemia, often pyuria. In imaging tests the kidney is enlarged, with shape preserved, it can contain deposits in the calyces and pelvic system and numerous hypoechogenic changes corresponding to abscesses. Urography and renal scintigraphy usually show impaired organ function [1,2,5].

The test of choice in the suspicion of pyelonephritis xantogranulomatous is computed tomography, which allows to assess the advancement of the process and infiltration of adjacent tissues [1,4,5].

In differential diagnosis in children, the Wilms tumor, neuroblastoma, clear cell carcinoma, inflammatory process in the form of pyonephrosis, kidney tuberculosis, kidney abscess should be considered [4].

In cases of limited inflammation, an attempt is made to conservative treatment, but in most cases of diffuse process, nephrectomy turns out to be the only effective treatment [1,2,4].

The final diagnosis can be made on the basis of histopathological examination, where the kidney tissue is replaced by infiltrates of mononuclear lipid-laden macrophages, so-called foam cells [2,3,4].

## Case description

### Case 1

The authors present a case of less than 3-year-old girl treated for left kidney pyelonephritis xantogranulomatosa.

About a year before admission, the patient started reporting pain during micturition. Redness of the external urethra was found, urinary tract infection was diagnosed and treated with Amoxicillin (July 2016), followed by prophylactic furazidone for approximately 12 months.

Abdominal ultrasound was performed due to the persistence of the symptoms (I 2017), finding in the lower calyx of the left kidney 2 deposits of 7 mm and 11 mm, and the remaining calyces of this kidney filled with hyperechogenic urine, with small reflections.

In the next US (July 2017) it was found: (1) in the left kidney, the heterogeneous renal cortex, with focal lesions of the average diameter about 18mm, with hyperechogenic, calcified walls – this picture has not been present in the study so far; (2) in the calyx-pelvis system, shading structures with a total dimension of 16 mm, probably shading deposits, each approx. 8 mm, a progression compared to the previous study. The patient was qualified for planned diagnosis of urolithiasis. Repeated urinalysis showed no abnormalities, and urine cultures were sterile. The patient was hospitalized several times due to inflammatory changes in the lungs. In August

2016 she was treated with Amoxicillin due to pharyngitis; infestation of ootosis and ascariasis, and microcytic anemia were diagnosed. She periodically reported burning of the vulva during micturition. Parents reported a lack of appetite in the child, insufficient weight gain was found (200 g in 9 months).

In September 2017, one year after the onset of symptoms, at the admission to the Department of Pediatrics, Nephrology and Allergology of the Military Institute of Medicine, the child was in good general condition. In physical examination there was inflammation of the corners of the mouth, the suppression of reverberation on the right side under scapula, the left kidney was palpable. In additional tests, the exponents of inflammation increased (WBC 19.5 thousand, Neutrophils 65%, CRP 21.3 mg/dl, passive reaction 64 mm/h), microcytic anemia, normal renal and hepatic function parameters, no signs of urinary tract infection, elevated concentration of D-dimers and fibrinogen were found. Chest X-ray showed bilateral cavital consolidations. Pneumonia was diagnosed and empiric antibiotic therapy (Ceftriaxon IV) was administered, and a slight reduction in inflammatory markers was obtained. Suspecting the atypical etiology, Clarithromycin was introduced in the treatment. In control tests, inflammatory factors were observed to increase, previous antibiotic therapy was changed to Ceftazidime and Amikacin IV.

In the ultrasound the liver was enlarged, 113 mm long, with somewhat inhomogeneous echogenicity, with no focal changes, kidneys in typical location, moving while breathing, the right 89 mm, the left 108 mm. In the left kidney the cortical layer was inhomogeneous, hypertrophied, with faded corticomedullary differentiation, in the pelvis there were deposits of 17 mm and 8 mm; the renal pelvis system of the right kidney and both ureters were normal. In the next test the left kidney enlarged to 115 mm, with faded corticomedullary differentiation, was swollen, in the area of the lower pole, outside the kidney capsule, an inhomogeneous hypoechogenic change of 43x22 mm (abscess?) was found.

In computed tomography with the urographic phase, the kidney was significantly enlarged, mainly in the axial dimension, with the features of doubling the pelvic and calyx system. The upper part of the kidney was with normal thickness of the parenchyma and corticomedullary differentiation with moderately enlarged kidney calyces. The lower renal pelvis of the left kidney probably occluded, surrounded by contrasting inflammatory fibrous tissue, in the pelvic lumen there was 17x8 mm calcified casting; significantly widened renal calyces of the lower renal parenchyma contained homogeneous hypodense content – the image suggested dense fluid content.

Клінічний випадок

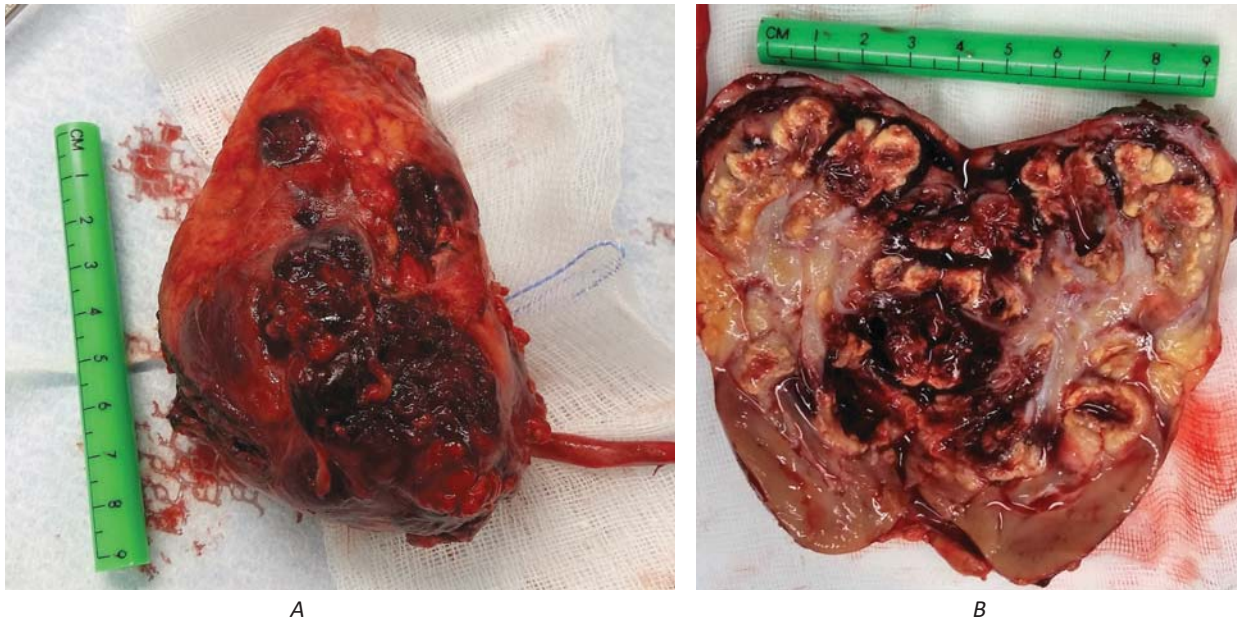


Fig.1. Left kidney, case 1: A – external appearance, B – internal appearance

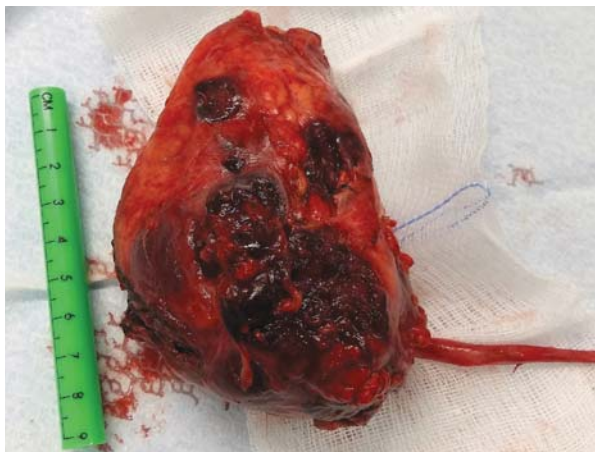

Fig.2. Left kidney, case 2, internal appearance

In the left renal space, along the posterior renal fascia, polycyclic, fluid reservoirs with a maximum transverse dimension of approximately 30x20 mm (most likely abscesses), and free fluid were found. «The picture may correspond to complicated pyelonephritis xantogranulomatosa of the left kidney». The left ureter narrowed below the renal pelvis. Numerous enlarged lymph nodes on the course of kidney vessels, and free fluid in the retroperitoneal excavation were found.

Due to progressive anemia (Hb 8.5 g/dl) red blood cell concentrate was transfused.

After urological consultation the girl was qualified for urgent nephrectomy and was referred for further treatment at the Department of Pediatric Surgery and Pediatric Urology in Dziekanów Leśny.

Incision was done in the left subcostal-lumbar region. The tumor boundaries reached the midline of the body, the left hip and the left subphrenic region. The peritoneum was removed in stages. Perirenal abscesses were opened during the preparation. The cultures were harvested. The kidney was separated from the surrounding tissues. With argon coagulation, the renal parenchyma was punctured, the pelvic system reached and the pus exuded from the inside of the kidney. The kidney was completely removed together with the upper part of the ureter. (Fig. 1, A, B) The renal area was rinsed with Gentamycin, and a drain was left. 260 ml of PRBC were transfused.

*Proteus mirabilis* was found in the culture of abscesses.

The early postoperative course was complicated by paralytic occlusion of the gastrointestinal tract, very high inflammatory markers (CRP 494.6 mg/dl, PCT 5.74 ng/ml, WBC 24, 32 thousand, Neut 83.3% Plt 851 thousand) and transient diuresis disorders were observed, forced diuresis – furosemide, dopamine. The patient received Amikacin, Cylastatin with Imipenem, Vancomycin; then after the culture was found, Vancomycin was discontinued, and Ceftriaxone was introduced, Nystatin, and *Lactobacillus rhamnosus*.

Hepatic and renal parameters as well as urine tests were normal throughout the whole period of the disease.

Further postoperative course correct.

Standardization of inflammatory parameters was obtained. Histopathological examination confirmed the diagnosis of pyelonephritis xantogranulomatosa of the left kidney.

The girl was discharged home in a good general and local condition.

The patient remains under outpatient control. She does not report any complaints. Except the scar after nephrectomy, there are no abnormalities in physical examination, normal appetite, normal weight gain, abdominal ultrasound without pathology, and normal laboratory blood and urine tests.

### Case 2

Girl, 11 years old, admitted with diagnosis of a left kidney abscess.

In an interview she reported for about a month high fever and lower urinary tract symptoms. Initially was treated as outpatient. Ten days before admission to the Department of Pediatrics, she was highly feverish, reported difficult urination and cough. She had been treated with Roxithromycin for seven days and 1-day with Furazidine without effect.

Then she was treated in the Department of Pediatrics at the district hospital. On admission she was in a quite good general condition, with high indicators of inflammation, and moderate leukocyturia (25/hpf). Cefotaxime followed by Ceftazidime were administered. Due to the persistent hectic fever on the 6th day of hospitalization, ultrasound was performed, which revealed a change corresponding to abscess of the left kidney. The diagnosis was confirmed in computed tomography and the girl was referred to the Pediatric Surgery and Pediatric Urology Clinic, CMPE.

At admission, the girl was in a quite good general condition with a positive Goldflamm sign on the left side. The inflammatory exponents significantly increased (CRP 223.5 mg/L N<10, WBC 17.83, Neut 80%). After administration of Imipenem and Amikacin, puncture and drainage of the lumbar abscess was performed. During the procedure, suspicion of xantogranulomatous pyelonephritis was raised.

During the postoperative period, the patient's mood improved, the body temperature remained normal, there was a slight decrease in the inflammatory markers (97 mg/l), followed by another increase to 188 mg/l.

In an abscess culture: *E. coli* were quite numerous.

On the third postoperative day US found an area of the residual abscess with a diameter of about 17 mm, circumferentially small band-like hyperechoegenic areas – the possibility of infiltration of perirenal fat tissue.

On the fifth day after the abscess drainage, extensive inflammation including perirenal fat tissue, renal fascia, and peritoneal fat near the splenic colon were described in computed tomography. In order to confirm or rule out the inflammatory process of the type of

pyelonephritis xantogranulomatosa of the kidney, NMR was performed.

Due to the extent of the inflammatory process, left-sided nephrectomy was performed (Fig. 2).

During the procedure, 2 units of red blood cells concentrate were transfused.

In the first days after the surgery, high exponents of inflammation persisted. Antibiotic therapy was used: Imipenem, Amikacin and Metronidazole. On the fourth day after surgery, the Foley catheter and drains were removed from the kidney bed. Normalisation of laboratory exponents and gradual improvement of the general condition followed. The post-operative wound healed correctly.

The patient was discharged home in a good general condition.

Under outpatient control without complaints; a month after the surgery the ultrasound showed no pathology.

### Discussion

Pyelonephritis xantogranulomatosa is a very rare form of chronic kidney inflammation with unclear causes. The literature shows the relationship of the disease with disorders in urinary outflow, stones, infections and prolonged antibiotic therapy [2–5]. In the first patient, pyelonephritis xantogranulomatosa occurred in the doubled kidney, in the lower system, then covering the entire organ; additionally, the presence of deposits in the kidney changed by inflammation was found. It should also be noted that both patients in the period preceding the diagnosis were subjected to long-term antibiotic therapy due to recurrent respiratory infections and chronic urinary tract infections. Treatment of the first patient was one-stage due to the intensification of the inflammatory process at the time of diagnosis. In the second patient, an attempt was made to save the kidney by draining the abscess, and in the next stage, because of the expansion of the process – nephrectomy was performed on the 10th day of the disease. *Proteus mirabilis* and *Escherichia coli* were found in the cultures, which are also reported in the literature as the most common pathogens [2,5]. It is interesting that only one kidney is involved in the process, despite the generalized inflammatory reaction.

The diagnosis of pyelonephritis xantogranulomatosa is complicated and confirmation of the diagnosis is possible only on the basis of histopathological examination. In imaging studies, the kidney is enlarged, with shape preserved, it can contain deposits in the calyx and pelvic system and numerous hypoechogenic changes corresponding to abscesses. Urography and

## Клінічний випадок

renal scintigraphy usually show impaired organ function. The test of choice in the suspicion of pyelonephritis xantogranulomatosa is computed tomography, which allows to assess the advancement of the process and infiltration of adjacent tissues [1,2,4,5]. In differential diagnosis in children, the Wilms tumor, neuroblastoma, clear cell carcinoma, inflammatory process in the form of pyonephrosis, kidney tuberculosis, kidney abscess should be considered [4].

In both cases described, the diagnosis of xantogranulomatosa was confirmed in histopathological examination. Qualification for nephrectomy was based on imaging studies (CT and NMR) and persistent high exponents of infection. In the opinion of the authors, the diagnosis based on imaging studies requires a lot of experience, which is difficult to obtain due to the occasional occurrence of the disease described.

## Conclusions

Pyelonephritis xantogranulomatosa should be suspected in all children with kidney, perirenal or psoas abscess and with urine outflow obstruction, renal mass and / or non-functioning kidney with or without urolithiasis [1]. Patients should be directed to highly specialized centers.

### Відомості про авторів:

**Szymanek-Szwed Magdalena** – Department of Pediatric Surgery and Pediatric Urology, Centre of Postgraduate Medical Education, Dziekanów Leśny, Warsaw, Poland. For correspondence: e-mail: [HYPERLINK "mailto:magdalena.szwed@szpitaldziekanow.pl"magdalena.szwed@szpitaldziekanow.pl](mailto:magdalena.szwed@szpitaldziekanow.pl)

**Załęska-Oracka Katarzyna** – Department of Pediatric Surgery and Pediatric Urology, Centre of Postgraduate Medical Education, Dziekanów Leśny, Warsaw, Poland.

**Samotyjek Joanna** – Department of Pediatric Surgery and Pediatric Urology, Centre of Postgraduate Medical Education, Dziekanów Leśny, Warsaw, Poland.

**Jobs Katarzyna** – Department of Pediatric Surgery and Pediatric Urology, Centre of Postgraduate Medical Education, Dziekanów Leśny, Warsaw, Poland.

**Jurkiewicz Beata** – prof. CMKP, Head of the Department of Paediatrics, Nephrology and Allergology, Children's Military Institute of Medicine, Warsaw, Poland.

Стаття надійшла до редакції 18.03.2019 р., прийнята до друку 14.06.2019 р.

In justified cases, an attempt can be made to preserve the kidney, but in most cases nephrectomy remains the only effective treatment, whereas some authors emphasize the importance of percutaneous drainage prior to surgery [1,3–5].

The researches were carried out in accordance with the principles of the Helsinki Declaration.

The informed consent of the patient was obtained for conducting the studies.

*The authors declare they have no conflict of interest.*

### References

1. Bingöl-Koloğlu M1, Ciftçi AO, Senocak ME, Tanyel FC, Karnak I, Büyükpamukçu N. (2002, Feb). Xantogranulomatous Pyelonephritis in children: diagnostic and therapeutic aspects. *Eur J Pediatr Surg.* 12(1): 42-8. PMID: 11967759
2. Chieh-Min Fan, Whitman GJ, Chew FS. (1995). Xantogranulomatous Pyelonephritis. *AJR.* 165: 862. 0361-803X/95/1654-862
3. Godlewski D, Pabiś S, Tereszkiewicz J, Mazurkiewicz M. (2011). Laparoscopic treatment of Xantogranulomatous Pyelonephritis – a case description. *Onkologia i Radioterapia* 2(16).
4. Jong Kil Nam, Sung Woo Park, Sang Don Lee, Moon Kee Chung. (2012). Xantogranulomatous Pyelonephritis in Korean Children. *Yonsei Med J.* 53(6): 1159-1164. PMID: 23074117
5. Leoni FA1, Kinleiner P, Revol M, Zaya A, Odicio A. (2009, May). Xantogranulomatous Pyelonephritis: Review of 10 cases. *Arch Esp Urol.* 62(4): 259-71. PMID:19717876