

T. Ghi, T. Eggebo, C. Lees, K. Kalache, P. Rozenberg,
A. Youssef, L. J. Salomon, B. Tutschek

ISUOG Practice Guidelines: intrapartum ultrasound

First published: 04 July 2018

<https://doi.org/10.1002/uog.19072>

Published: *Ultrasound Obstet Gynecol.* 2018; 52: 128-139.

Abstract

Purpose and scope

The purpose of these Guidelines is to review the published techniques of ultrasound in labor and their practical applications, to summarize the level of evidence regarding the use of ultrasound in labor and to provide guidance to practitioners on when ultrasound in labor is clinically indicated and how the sonographic findings may affect labor management. We do not imply or suggest that ultrasound in labor is a necessary standard of care.

Clinical Standards Committee

The International Society of Ultrasound in Obstetrics and Gynecology (ISUOG) is a scientific organization that encourages sound clinical practice and high-quality teaching and research related to diagnostic imaging in women's healthcare. The ISUOG Clinical Standards Committee (CSC) has a remit to develop Practice Guidelines and Consensus Statements as educational recommendations that provide healthcare practitioners with a consensus-based approach, from experts, for diagnostic imaging. They are intended to reflect what is considered by ISUOG to be the best practice at the time at which they were issued. Although ISUOG has made every effort to ensure that Guidelines are accurate when issued, neither the Society nor any of its employees or members accepts any liability for the consequences of any inaccurate or misleading data, opinions or statements issued by the CSC. The ISUOG CSC documents are not intended to establish a legal standard of care, because interpretation of the evidence that underpins the Guidelines may be influenced by individual circumstances, local protocol and available resources. Approved Guidelines can be distributed freely with the permission of ISUOG (info@isuog.org).

Purpose and scope

The purpose of these Guidelines is to review the published techniques of ultrasound in labor

and their practical applications, to summarize the level of evidence regarding the use of ultrasound in labor and to provide guidance to practitioners on when ultrasound in labor is clinically indicated and how the sonographic findings may affect labor management. We do not imply or suggest that ultrasound in labor is a necessary standard of care.

Background and introduction

Traditionally, the assessment and management of a woman in labor is based upon clinical findings [1–7]. The diagnosis of arrest of labor and decisions regarding the timing or type of intervention rely mostly on digital evaluation of cervical dilatation and fetal head station and position [8–17]. However, clinical examination of head station and position is inaccurate and subjective [18–25], especially when caput succedaneum impairs palpation of the sutures and fontanelles.

The use of ultrasound has been proposed to aid in the management of labor. Several studies have demonstrated that ultrasound examination is more accurate and reproducible than clinical examination in the diagnosis of fetal head position and station [9–33] and in the prediction of arrest of labor [34–42]. Ultrasound examination can, to some extent, distinguish those women destined for spontaneous vaginal delivery and those destined for operative delivery [43–47]. Furthermore, there is growing evidence that ultrasound in labor may predict the outcome of instrumental vaginal delivery [44–48].

Ultrasound in labor can be performed using a transabdominal approach, mainly to determine head and spine position [49], or a transperineal approach, for assessment of head station and position at low stations. Several quantitative sonographic parameters have been proposed to assess head station [30–32, 34, 35, 40, 42, 43, 50, 51]. Currently, there is no consensus regarding when in labor ultrasound should be performed, which parameter(s) should be obtained and how the sonographic findings should be integrated into clinical

practice in order to improve management of the patient.

Identification and assessment of evidence

The Cochrane Library and Cochrane Register of Controlled Trials were searched for relevant randomized controlled trials, systematic reviews and meta-analyses. A search of Medline from 1966 to 2017 was also carried out. The date of the last search was 30 September 2017. In addition, relevant conference proceedings and abstracts were searched. Searches used the relevant MeSH terms, including all subheadings. This was combined with a keyword search, including: 'labor ultrasound', 'transperineal ultrasound', 'fetal head station', 'fetal occiput position' and 'instrumental vaginal delivery'. When possible, recommendations in these Guidelines are based on, and explicitly linked to, supporting evidence. Details of the grades of recommendation and levels of evidence used in these Guidelines are given in Appendix 1.

Guidelines

Aims of ultrasound in the labor ward

These Guidelines address exclusively the use of ultrasound in labor to determine fetal head station, position and attitude. All other applications of ultrasound in the labor ward, such as assessment of cervical length or dilatation and fetal Doppler studies, are not covered. For the time being, ultrasound should be used as an adjunctive method and not as a substitute for clinically indicated digital vaginal examination.

Assessment of fetal head position

Precise knowledge of fetal occiput position in labor is of paramount importance.

- Persistent occiput-posterior position is associated with higher risk of operative delivery [52] and maternal and perinatal morbidity [53, 54].
- Correct determination of head position is crucial before instrumental delivery. An error in evaluation of head position may result in inappropriate vacuum or forceps placement, increasing the potential for fetal injury and the failure rate of the procedure [55–58]. Failed instrumental delivery followed by Cesarean section is associated with an increased decision-to-delivery interval [59] and an increased risk of maternal [60, 61] and fetal [62–65] trauma.

Traditionally, clinicians determine fetal head position by palpating the sagittal suture and the anterior and posterior fontanelles. Several studies have evaluated the accuracy of clinical diagnosis of fetal head position, using ultrasound [19–28]

or position-tracking technology systems [66] as reference; digital palpation was found to be subjective. Studies show consistently that digital examination to determine head position is inaccurate, with a rate of error ranging from 20% to 70%, when considering ultrasound as the standard [19] (**Level of evidence: 1-**).

Clinical evaluation by palpation tends to be even less accurate in cases of abnormal head position, such as occiput posterior or transverse, when medical intervention is more likely to be needed [19, 20, 22, 23] (**Level of evidence: 2++**).

This inaccuracy may be exaggerated by the presence of caput succedaneum and asynclitism, both of which are frequently associated with obstructed labor. Several studies have failed to demonstrate a significant difference in accuracy between experienced and inexperienced obstetricians [19, 21, 22], although this finding has been questioned by others [20] (**Level of evidence: 2+**).

Various studies have demonstrated the superiority of ultrasound alone or in combination with digital examination in the precise determination of fetal head rotation as compared with traditional digital examination alone [19–28, 66] (**Level of evidence: 1-**).

Assessment of fetal head station

The fetal head station is the level of the fetal head in the birth canal relative to the plane of the maternal ischial spines (non-cephalic presentation is not considered in these Guidelines). The term 'head engagement' is used when the widest part of the head passes into the pelvic inlet or two-fifths or less of the fetal head is palpable abdominally, corresponding to descent of the biparietal plane of the fetal head to a level below that of the pelvic inlet [67]. On digital vaginal examination, the fetal head is considered engaged when the leading part of the skull has reached the imaginary line or plane between the maternal ischial spines. This head station is referred to as station 0. Higher or lower head stations are expressed in centimeters above (negative) or below (positive) this reference plane, respectively.

The subjectivity of transvaginal digital assessment of fetal head station was demonstrated by Dupuis et al. [18] (**Level of evidence: 2+**). Using a birth simulator equipped with a sensor, they placed a fetal head mannequin at defined stations according to the American College of Obstetricians and Gynecologists, and a group of examiners of various levels of experience used palpation to classify the fetal head station as high, mid-pelvis, low or outlet. The mean 'category'

error was 30% for residents and 34% for obstetricians. More importantly, the incorrect diagnosis of a mid-pelvic station rather than a true high-pelvic station accounted for the majority of errors (88% and 67% by residents and obstetricians, respectively). In clinical practice, such misclassification may impact adversely on the management of labor.

Ultrasound examination documents objectively and precisely the fetal head station in the birth canal [29-33, 35, 47, 68] (**Level of evidence: 2+**).

A series of sonographic parameters have been suggested to describe the fetal head station; these have been demonstrated to have high intra- and interobserver agreement [69-71] (**Level of evidence: 2+**).

Assessment of fetal head descent (progression)

Some observational studies [36, 37, 39, 72, 73] have suggested that repeat ultrasound examinations to assess the change of head station over time ('progression') performs better than does digital examination in documenting fetal head descent and in demonstrating slow labor or lack of progress in both the first and second stages (**Level of evidence: 2+**).

Assessment of fetal head attitude

The fetal head attitude is the relationship of the fetal head to spine. Ultrasound has proved helpful in visual assessment of fetal head attitude [74, 75] (**Level of evidence: 2-**) and in the objective diagnosis of fetal head malpresentation in labor [76-80] (**Level of evidence: 3**).

Technique

Ultrasound assessment in labor may be performed using a transabdominal or transperineal approach, depending on the parameter that is the aim of the examination (mainly position and station) and on the clinical indication. A two-dimensional ultrasound machine equipped with a convex probe, such as that used for transabdominal fetal ultrasound for biometry and assessment of anatomy, is used. Suggested requirements of equipment for use in the labor ward are that it is quick to start up, and has batteries with a long life and that are quick to recharge. A wide-sector, low-frequency (< 4 MHz) insonation is best suited to ultrasound in labor.

Assessment of fetal head position

Sonographic assessment of fetal head position is best performed by transabdominal imaging in axial and sagittal planes [81]. Placing the ultrasound probe transversely on the maternal abdomen, an axial view of the fetal trunk is obtained at the level of the fetal upper abdomen or chest. The position of the fetal spine may then be deter-

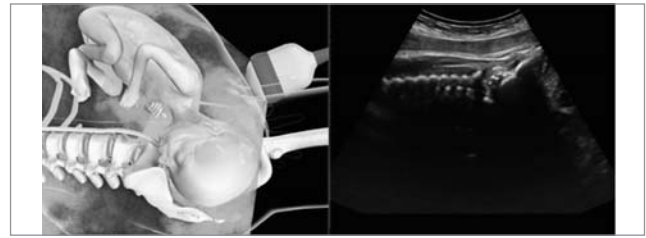


Fig. 1. Transabdominal ultrasound imaging (sagittal plane) in fetus with occiput-anterior position. (Reproduced from Youssef et al. [81])

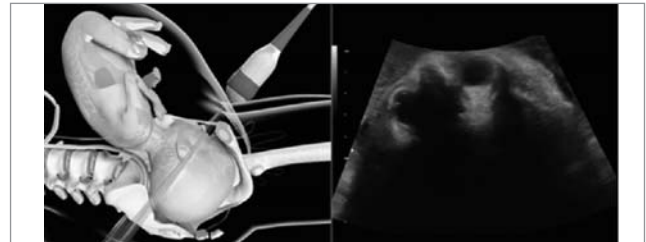


Fig. 2. Transabdominal ultrasound imaging (transverse plane) in fetus with occiput-posterior position. (Reproduced from Youssef et al. [81])

mined. The ultrasound transducer is then moved downwards until it reaches the maternal suprapubic region, visualizing the fetal head. The landmarks depicting fetal occiput position are the two fetal orbits for occiput posterior, the midline cerebral echo for occiput transverse, and the occiput itself and the cervical spine for occiput-anterior position [81] (Fig. 1, 2). The choroid plexus, which diverges towards the occiput, can be helpful in determining fetal head position [47].

The midline structures in the fetal head may be difficult to visualize on transabdominal imaging at low fetal head stations. Combining a transabdominal with a transperineal ultrasound approach may be recommended in these cases for precise determination of position.

Position can be described by depicting a circle, like a clock (Fig. 3): positions ≥ 02.30 h and ≤ 03.30 h should be recorded as left occiput transverse (LOT); positions ≥ 08.30 h and ≤ 09.30 h as

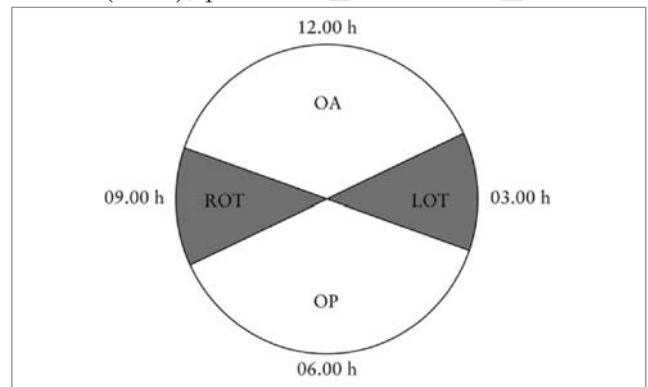


Fig. 3. Classification of fetal occiput position based on positions of hour hand on a clock face: positions ≥ 02.30 h and ≤ 03.30 h should be recorded as left occiput transverse (LOT) and positions ≥ 08.30 h and ≤ 09.30 h as right occiput transverse (ROT). Positions > 03.30 h and < 08.30 h are occiput posterior (OP) and positions > 09.30 h and < 02.30 h are occiput anterior (OA) [92, 93].

right occiput transverse (ROT); positions > 03.30h and < 08.30h should be recorded as occiput posterior; and positions > 09.30h and < 02.30h as occiput anterior [25].

Assessment of fetal head station

Sonographic assessment of fetal head station is best performed by transperineal ultrasound in the midsagittal or axial plane. The probe is placed between the two labia majora or more caudally, at the level of the fourchette, with the woman in a semirecumbent position, with legs flexed at the hips and knees at 45° and 90° degrees, respectively. It is essential that her bladder is empty. In the midsagittal plane, the following anatomical landmarks are clearly depicted:

- pubic symphysis joint, as an oblong, irregular, echogenic structure; ideally displayed in a horizontal position;
- fetal skull, with anterior and posterior tabula.

The traditional reference plane of vaginal palpation, the level of the ischial spines, cannot be seen in this view. However, there is a fixed anatomical relationship between the lower end of the pubic symphysis and the interischial plane: the 'infrapubic line' is an imaginary line originating from the caudal end of the symphysis pubis, perpendicular to its long axis, extending to the dorsal part of the birth canal. In three-dimensional reconstructions of computed tomographic data from a normal female bony pelvis, the infrapubic line has been shown to be 3 cm above the plane of the ischial spines [42, 82-84].

On transperineal imaging in the midsagittal plane, several parameters have been proposed that use the pubic symphysis as landmark and reference point for quantitative measurements. Three indicate head station directly: the angle of progression (AoP), also called the 'angle of descent' [40, 43]; the progression distance (PD) [30]; and the transperineal ultrasound head station [41]. Others indicate it indirectly: the head-symphysis distance (HSD) is an indirect parameter that changes with descent [51]; and the head direction indicates the direction of the longest recognizable axis of the fetal head with respect to the long axis of the pubic symphysis [42].

With simple clockwise rotation of the transducer by 90°, an axial plane is obtained, in which two additional parameters can be evaluated and measured: the head-perineum distance (HPD) [34], as a marker of head station; and the midline angle (MLA) [31], which assesses rotation of the head.

Angle of progression (AoP)/angle of descent

The AoP is the angle between the long axis of the pubic bone and a line from the lowest edge

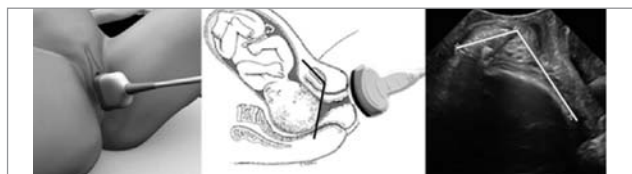


Fig. 4. Measurement of angle of progression, showing placement of transducer and how angle is measured (images courtesy of A. Youssef, E. A. Torkildsen and T.M. Eggebo)

of the pubis drawn tangential to the deepest bony part of the fetal skull (Fig. 4). It was first described in 2009 [40, 43] and has been found to be an accurate and reproducible parameter for assessment of fetal head descent [40, 41, 69, 70] (**Level of evidence: 2+**). Duckelmann et al. [72] demonstrated that measurement of AoP can be learned easily, regardless of the clinician's level of ultrasound experience (**Level of evidence: 2+**). In their investigation of several different parameters, Tutschek et al. [41] compared AoP and transperineal ultrasound head station, finding that fetal head station 0 corresponds to an AoP of 116 (Table 1).

- Adapted from Tutschek et al. [41].
- TPU head station calculated using formula obtained by regression of head station over angle of progression (TPU head station (cm) = AoP (°) x 0.0937 – 10.911).

Fetal head direction

Head direction, an indirect marker of head station, was first described by Henrich et al. [42], as the angle between the longest recognizable axis of the fetal head and the long axis of the pubic symphysis, measured in a midsagittal transperineal view (- Fig. 5). It was classified categorically as 'head down' (angle < 0°), 'horizontal' (angle 0°-30°) and 'head up' (angle > 30°). The authors noted an easily recognizable change in head direction as it descends towards the pelvic floor, from downward to horizontal to upward. Head up immediately before operative vaginal delivery (OVD) correlated with a successful and relatively easy (few tractions) procedure.

Sonographic head station

The transperineal ultrasound head station expresses head station on the scale conventiona-

Table 1

Conversion between angle of progression (AoP) and transperineal ultrasound (TPU) head station

AoP (°)	Head station (cm)	AoP (°)	Head station (cm)
84	-3.0	132	1.5
90	-2.5	138	2.0
95	-2.0	143	2.5
100	-1.5	148	3.0
106	-1.0	154	3.5
111	-0.5	159	4.0
116	0.0	164	4.5
122	0.5	170	5.0
127	1.0		

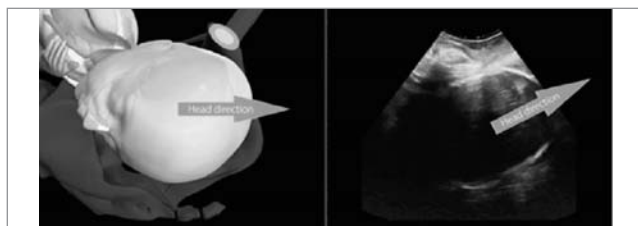


Fig. 5. Fetal head direction: horizontal (left) and head up (right)

lly used for palpatory assessment of progress of labor (cm above or below the ischial spine plane) and incorporates the curvature of the birth canal. It requires assessment of: (i) the head direction (see above) and (ii) the distance between the infrapubic plane (which is 3 cm above the ischial plane) and the deepest presenting bony part along the line of head direction (Fig. 6). Transperineal ultrasound head station has been compared with other parameters of fetal head station. While it is more complex to measure (requiring both angle and distance measurements), it was found to correlate linearly with the easily measurable AoP: the relationship between these two parameters thus allows direct conversion of AoP measurements into centimeters on the conventional palpation scale (Table 1).

Head-perineum distance (HPD)

HPD was first described by Eggebo et al. [34] (Fig. 7). The transducer should be placed between the labia majora (in the posterior fourchette), and the soft tissue compressed completely against the pubic bone. The transducer should be angled until the skull contour is as clear as possible, indicating that the ultrasound beam is perpendicular to the fetal skull. HPD is measured in a frontal transperineal scan as the shortest distance from the outer bony limit of the fetal skull to the perineum. This distance represents the part of the birth canal yet to be passed by the fetus.

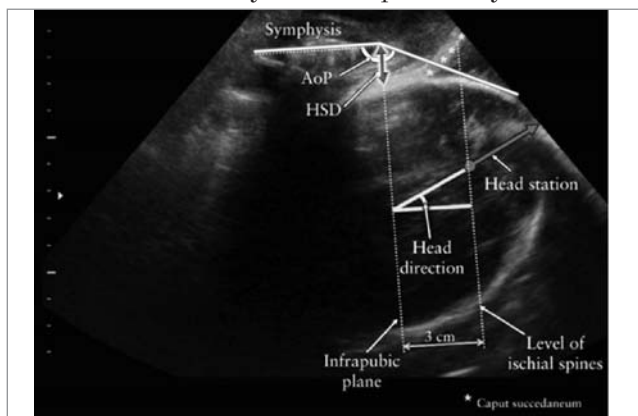


Fig. 6. Transperineal ultrasound head station should be measured along line of head direction. Angle of progression (AoP), head-symphysis distance (HSD), and, as reference planes, measurable infrapubic plane and inferred ischial plane, are also shown (modified from Tutschek et al. [32])

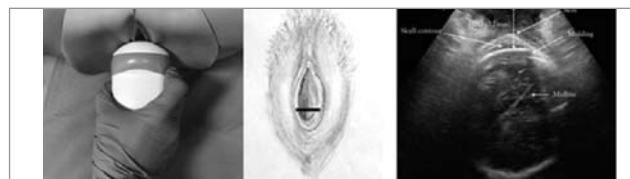

Fig. 7. Measurement of head-perineum distance (HPD), showing placement of transducer and how distance is measured (images courtesy of S. Benediktsdottir, I. Froysa and J. K. Iversen).

Women do not find this compression of the soft tissue to be painful [36].

HPD cannot be compared directly with the clinical assessment of fetal head station (from -5 to +5) because HPD does not follow the curve of the birth canal [36]. Tutschek et al. [32] found head station 0 to correspond to a HPD of 36 mm, Kahrs et al. [47] found head station 0 to correspond to a HPD of 35 mm and Maticot-Baptista et al. [85] found a HPD of 38 mm to correspond to midcavity. Limits of agreement for interobserver measurement variation were reported as -8.5 to +12.3 mm [34].

Midline angle (MLA)

MLA differs from the other parameters as it utilizes the angle of head rotation as an indicator of birth progress. First described by Ghi et al. [31], it is measured in the axial plane using a transperineal approach: the echogenic line interposed between the two cerebral hemispheres (midline) is identified, and MLA is the angle between this line and the anteroposterior axis of the maternal pelvis (Fig. 8). They found a significant correlation between head station assessed clinically and rotation as represented by MLA. After excluding occiput posterior cases, they found a rotation $\geq 45^\circ$ to correspond to a head station of $\leq +2$ cm in 70/71 (98.6%) cases and a rotation $< 45^\circ$ to correspond to a head station of $\geq +3$ cm in 41/49 (83.7%) cases ($P < 0.001$) (Level of evidence: 2+). Although MLA was originally described as an angle in relation to the maternal pelvis, head position can be represented using positions on a clock face in the same way as described for transabdominal imaging.

Additional parameters to assess fetal head station

Two further parameters have been proposed to measure the fetal head station in labor: progression distance (PD) and head-symphysis distance (HSD). However, they have not been applied widely in research studies and their clinical usefulness is less well established than that of the other parameters.

PD was first described as an objective measurement of fetal head engagement, taken before onset of labor, by Dietz and Lanzarone [30]. It is defined as the minimum distance between the 'infrapubic line' and the presenting part (defined as the most

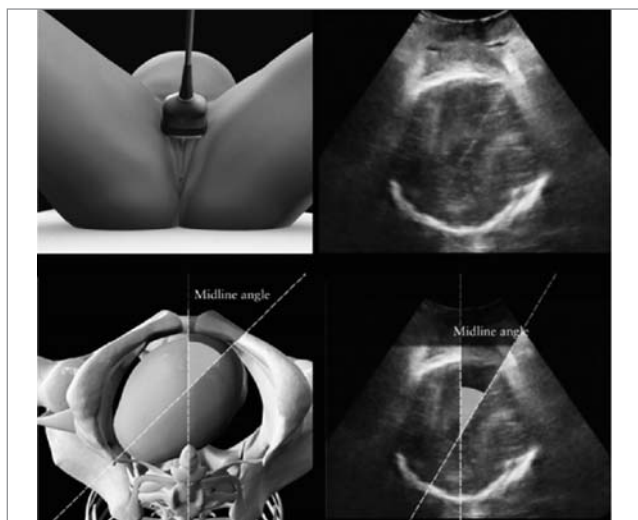


Fig. 8. Measurement of midline angle, showing placement of transducer and how angle is measured

distal part of the hyperechogenic curvature signifying the fetal skull) (Fig. 9). Because AoP is easier to measure than PD and accounts for the curved nature of the birth canal, which PD does not, the former should be preferred as a measure of head station.

HSD is the distance between the lower edge of the maternal symphysis pubis and the fetal skull, along the infrapubic line (Fig. 10). As the palpable space between the fetal skull and the maternal symphysis pubis is used widely in clinical practice as a proxy for fetal head station, the HSD has been proposed by Youssef et al. [51] as an indirect marker of fetal head descent. In a cohort of occiput-anterior fetuses this parameter has been proved reproducible [51], showing a linear negative correlation with the palpated station and becoming progressively shorter as the head descends towards the pelvic floor (**Level of evidence: 2+**). Furthermore, HSD has been shown to correlate with the other sonographic measurements of fetal head station; it is correlated positively with HPD and negatively with AoP [32] (Fig. 11). It can be measured only at stations below the infrapubic line (i.e. ≥ -3 cm).

Indications for ultrasound evaluation in labor

- Slow progress or arrest of labor in the first stage

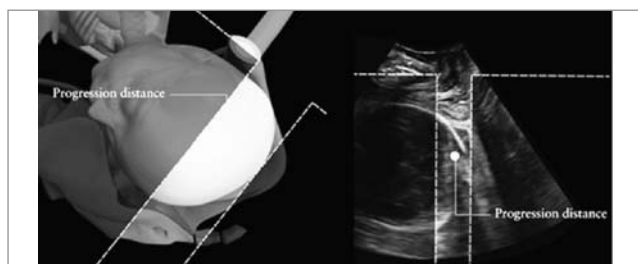


Fig. 9. Measurement of progression distance

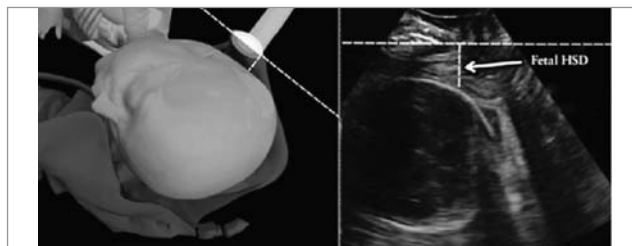


Fig. 10. Measurement of head-symphysis distance (HSD), showing placement of transducer and how distance is measured. (Reproduced from Youssef et al. [51])

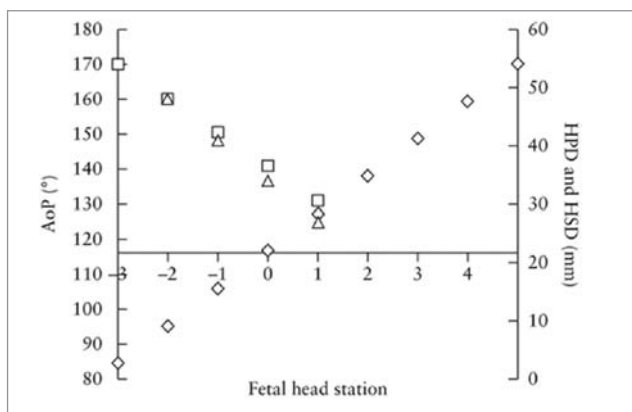


Fig. 11. Correlation of transperineal ultrasound (TPU) parameters representative of fetal head station: angle of progression (AoP; ◇); head-perineum distance (HPD; □); and head-symphysis distance (HSD; △). TPU head station is in cm above or below level of ischial spines. Data are from Tutschek et al. [32]

- Slow progress or arrest of labor in the second stage
- Ascertainment of fetal head position and station before considering or performing instrumental vaginal delivery
- Objective assessment of fetal head malpresentation

One study failed to demonstrate a benefit of routine use of ultrasound in labor for determination of head position (head station was not measured by ultrasound in this study) among low-risk patients, in whom its use was associated with a higher risk of Cesarean delivery [86] (**Level of evidence: 1-, grade of recommendation: A**).

Although ultrasound has been demonstrated to be more accurate and reproducible than digital examination in the determination of fetal head position and station in labor, knowledge of these findings has not been shown to improve the management of labor and delivery. Because of the rarity of adverse perinatal and maternal outcomes during labor, very large randomized studies would be necessary to prove a clinical benefit of intrapartum sonography for the fetus or the mother with respect to severe perinatal or maternal morbidity. However, intrapartum ultrasound allows more precise determination of position

and station and is more acceptable to women than digital examination [72]. Its use may be endorsed under the following circumstances as an adjunct to clinical examination.

Slow progress or arrest of labor in the first stage

Some consecutive studies have shown that HPD and AoP are more accurate than digital examination in predicting vaginal delivery in nulliparous women with prolonged first stage of labor [36, 39] (**Level of evidence: 2+, grade of recommendation: B**). In the largest multicenter trial, conducted on 150 women [39], if HPD was < 40 mm, the likelihood of Cesarean delivery was 7%, whereas it went up to 82% if HPD was > 50 mm. In the same study, if AoP was > 110°, the likelihood of Cesarean delivery was 12%, whereas this rose to 62% if AoP was < 100°.

In a study of the same population of 150 women with prolonged first stage of labor [37], the authors showed that occiput-posterior position, compared with non-occiput-posterior position, was significantly associated with the risk of Cesarean section (38% vs 17%, $P = 0.01$) (**Level of evidence: 2+, grade of recommendation: B**).

Several case reports or small series [76-80] have shown that, in patients with prolonged first stage of labor, transabdominal or transperineal ultrasound may identify as a cause of labor arrest different types of head malpresentation, including deflexed presentation (brow or face) or asynclitism (**Level of evidence: 3, grade of recommendation: C**).

Slow progress or arrest of labor in the second stage

There is a paucity of studies addressing specifically the usefulness of ultrasound in predicting the chance of spontaneous vaginal delivery compared with that of abdominal delivery or OVD in patients with prolonged second stage. In 62 women with prolonged second stage examined by transperineal ultrasound, Masturzo et al. [73] found that a favorable head direction (head up) was associated with spontaneous vaginal delivery in the majority (16/20; 80%) of cases, in contrast to downward (4/20; 20%) or horizontal (9/22; 41%) head direction (**Level of evidence: 2+, grade of recommendation: B**).

Ascertainment of fetal head position and station before instrumental vaginal delivery

In a recent randomized controlled trial [28], it was demonstrated that ultrasound assessment in addition to digital examination prior to instrumental vaginal delivery is significantly more accurate compared with digital examination alone

in the diagnosis of fetal head position (ultrasound diagnosis incorrect in 1.6% of cases, compared with 20.2% in digital examination group) (**Level of evidence: 1-, grade of recommendation: A**). While the study did not show significant differences in maternal or fetal morbidity, the main outcome was the accuracy of determining fetal position, and the study was not powered to detect differences in the occurrence of adverse events [87].

In their randomized controlled trial, Wong et al. [88] demonstrated that when fetal head position is determined by ultrasound compared with by palpation, placement of the suction cup was significantly closer to the flexion point (**Level of evidence: 1-, grade of recommendation: A**).

Head direction predicts the outcome of instrumental vaginal delivery [42]. When evaluated before vacuum extraction in protracted labor, the head-up sign is a positive predictor of success. Among 11 women with fetal head up and an occiput-anterior position, all had successful simple (5/11) or moderately difficult (6/11) vacuum extraction. In contrast, among the six cases with occiput-anterior fetus with head horizontal or down, only one vacuum extraction was simple, and the only case of failed extraction was observed in this group. The value of the head-up sign for prediction of vaginal delivery as well as its good intra- and interobserver agreement were subsequently confirmed by others [41] (**Level of evidence: 3, grade of recommendation: C**).

AoP was investigated as a predictor of successful vacuum delivery in 41 fetuses in occiput-anterior position. A cut-off value of 120° was found to predict an easy and successful vacuum extraction in 90% of cases [43] (**Level of evidence: 2+, grade of recommendation: B**).

In 52 women with occiput-anterior fetus undergoing vacuum delivery, the combination of head-up sign, MLA < 45° and AoP > 120° were found to be significant sonographic predictors of a successful procedure [45].

Cuerva et al. [46] assessed the role of ultrasound in predicting the outcome of forceps delivery in 30 non-occiput-posterior fetuses. They found that the smaller the AoP and the shorter the PD, the higher the risk of failure. AoP < 138° and PD < 4.8 cm were the strongest predictors of the nine complicated procedures (defined as requiring more than three tractions, failed procedure, or maternal or neonatal trauma) (**Level of evidence: 2+, grade of recommendation: B**).

A recent large study [44] investigated the relationship between vacuum extraction failure rate and AoP (immediately prior to application of the instru-

ment) in 235 women. In 30 (12%), the vacuum extraction failed, while in the remaining 205 it was successful. Failed vacuum delivery was associated with a significantly smaller median AoP (136.6° vs 145.9°); interestingly, the palpated head station did not differ between the two groups (2 vs 2 cm) (**Level of evidence: 2+, Level of evidence: B**).

In a European prospective study [47], transperineal ultrasound and the duration of vacuum extraction in a cohort of women with slow progress in the second stage of labor were assessed. Among the 222 women included, the duration of the extraction procedure was significantly shorter in women with HPD \leq 25 mm. The rate of Cesarean delivery was significantly lower among cases with HPD \leq 35 mm compared with those with HPD $>$ 35 mm (3.9% vs 22.0%, $P < 0.01$) and, if HPD $>$ 35 mm was combined with occiput-posterior position, the rate of Cesarean delivery was 35%. Furthermore, the incidence of umbilical artery pH $<$ 7.1 was significantly higher in the infants which underwent vacuum delivery with HPD $>$ 35 mm.

In a prospective cohort study including 659 women, the HPD (in this study referred to as the perineum-skull distance) was measured prior to OVD [48]. After adjustment for parity, presentation type and fetal macrosomia, HPD \geq 40 mm was significantly associated with the occurrence of a difficult extraction (odds ratio, 2.38; 95% CI, 1.51-3.74; $P = 0.0002$). Based on receiver-operating characteristics curve analysis, perineum-skull distance on ultrasound was a more accurate predictor of difficult OVD than was digital vaginal examination ($P = 0.036$).

Visual confirmation of fetal head malpresentation

Deflexed cephalic presentation or asynclitism is a major cause of obstructed labor [13, 14], estimated to account for one-third of Cesarean deliveries for arrest of labor [4-6, 8-10, 15-17]. In these cases the diagnosis is based traditionally upon digital examination in labor [89-91], although the use of ultrasound to support the clinical diagnosis has been reported recently [76-80] (**Level of evidence: 3, grade of recommendation: C**).

Summary

Ultrasound in active labor is not yet used widely, even though studies have shown that it is more precise and reproducible than clinical examination. Ultrasound allows objective measurement and precise documentation of findings obtained during the examination. Several sonographic parameters can be used during labor to assess mainly head station and position.

1. Head station can be measured objectively, for example by AoP or HPD, to assess current status and as a baseline for longitudinal measurements. It can also help to predict whether OVD is likely to be successful. Head station should be assessed transperineally, not transabdominally. HPD is straightforward to measure and is reproducible. AoP (in degrees) is equivalent to head station expressed in centimeters, from -3 cm to +5 cm (direct conversion is possible), and has the potential to link ultrasound data to traditional assessment by palpation. HPD and AoP/head station correlate linearly (for high station, i.e. higher than 0 to +1).

2. Head (and spine) position is assessed more accurately by transabdominal ultrasound than by digital palpation. Knowledge of head position in suspected delay or arrest of labor is important. Before OVD, knowledge of head position is essential.

3. MLA is assessed by transverse transperineal ultrasound and may help to decide whether OVD can be attempted safely.

4. Head direction is assessed by transperineal ultrasound and may help to decide whether OVD can be attempted safely.

There are two main situations in which ultrasound assessment is likely to be of particular use in labor.

1. Suspected delay or arrest of first or second stage. We recommend measurement of either AoP or HPD transperineally and assessment of head position transabdominally.

2. Potential need for performance of OVD. We recommend assessment of head position by transabdominal ultrasound and suggest measurement of fetal head station by transperineal ultrasound. The most reliable sonographic parameters to predict outcome of the procedure are HPD and AoP. MLA and/or head direction may also be useful to predict further the likelihood of success of the extraction.

What we know and what we don't

- We know that ultrasound allows more precise examination of fetal position and station than clinical examination.
- We know that women prefer ultrasound to digital examination in labor.
- We know that transabdominal ultrasound is used most commonly for fetal lie and position, and transperineal ultrasound can be used for head station.
- We don't know how this knowledge impacts on management of labor and maternal and neonatal outcomes.

Reporting

If an ultrasound examination is performed in labor, its results should be added to the clinical notes of the patient. For each sonographic evaluation, the following data should be noted:

- Fetal viability and heart rate
- Presentation of the fetus (cephalic, transverse, breech, oblique)
- Whether any part of the placenta is seen between presenting part and cervix
- Occiput and spine position

Based upon the judgement of the clinician, the following transperineal ultrasound parameters can be added in the second stage, especially before OVD (at rest or during contraction with maternal pushing; this should be noted):

- Angle of progression (AoP)
- Head-perineum distance (HPD)
- Head direction with respect to pubic symphysis
- Midline angle (MLA)

Guideline authors

These Guidelines were produced on behalf of the International Society of Ultrasound in Obstetrics and Gynecology (ISUOG) by the following authors, and peer reviewed by the Clinical Standards Committee.

T. Ghi, Obstetrics and Gynecology, University of Parma, Parma, Italy

T. Eggebo, National Center for Fetal Medicine, Trondheim University Hospital (St Olavs Hospital), Trondheim, Norway; Department of Obstetrics and Gynecology, Stavanger University Hospital, Stavanger, Norway

C. Lees, Centre for Fetal Care, Queen Charlottes and Chelsea Hospital, London, UK

K. Kalache, Sidra Medical and Research Center, Doha, Qatar

P. Rozenberg, Centre Hospitalier Poissy Saint Germain, Obstetrics & Gynaecology, Paris, France

A. Youssef, Obstetrics and Gynecology, S. Orsola Malpighi Hospital, Bologna, Italy

L. J. Salomon, Hopital Universitaire Necker-Enfants Malades, AP-HP, Universite Paris Descartes, Maternite, Paris, France; Societe Francaise pour l'Amelioration des Pratiques Echographiques, SFAPE

B. Tutschek, Prenatal Zurich, Heinrich-Heine-University, Medical Faculty, Zurich, Switzerland

Guideline external reviewers were V. Berghella, O. Dupuis and W. Lau. The final version

Levels of evidence and grades of recommendation used in these Guidelines

Classification of evidence levels	
1++	High-quality meta-analyses, systematic reviews of randomized controlled trials or randomized controlled trials with very low risk of bias
1+	Well-conducted meta-analyses, systematic reviews of randomized controlled trials or randomized controlled trials with low risk of bias
1-	Meta-analyses, systematic reviews of randomized controlled trials or randomized controlled trials with high risk of bias
2++	High-quality systematic reviews of case-control or cohort studies or high-quality case-control or cohort studies with very low risk of confounding, bias or chance and high probability that the relationship is causal
2+	Well-conducted case-control or cohort studies with low risk of confounding, bias or chance and moderate probability that the relationship is causal
2-	Case-control or cohort studies with high risk of confounding, bias or chance and significant risk that the relationship is not causal
3	Non-analytical studies, e.g. case reports, case series
4	Expert opinion
Grades of recommendation	
A	At least one meta-analysis, systematic review or randomized controlled trial rated as 1++ and applicable directly to the target population; or systematic review of randomized controlled trials or a body of evidence consisting principally of studies rated as 1+ applicable directly to the target population and demonstrating overall consistency of results
B	Body of evidence including studies rated as 2++ applicable directly to the target population and demonstrating overall consistency of results; or extrapolated evidence from studies rated as 1++ or 1+
C	Body of evidence including studies rated as 2+ applicable directly to the target population and demonstrating overall consistency of results; or extrapolated evidence from studies rated as 2++

is the responsibility of the Clinical Standards Committee of ISUOG. The guideline review process will commence in 2023 unless evidence requires earlier review.

Citation

These Guidelines should be cited as: 'Ghi T, Eggebo T, Lees C, Kalache K, Rozenberg P, Youssef A, Salomon LJ, Tutschek B. ISUOG Practice Guidelines: intrapartum ultrasound. *Ultrasound Obstet Gynecol* 2018; **52**: 128-139.'

References

https://obgyn.onlinelibrary.wiley.com/doi/full/10.1002/uog.19072-elq_mid=28630&elq_cid=2070070#.Wz9RGF2V IJw.email